Check for updates

Review Article

The Wonderful Colors of the Hematoxylin–Eosin Stain in Diagnostic Surgical Pathology

International Journal of Surgical Pathology
2014, Vol. 22(1) 12–32
© The Author(s) 2014
Reprints and permissions:
sagepub.com/journalsPermissions.nav
DOI: 10.1177/1066896913517939
ijs.sagepub.com
SAGE

John K. C. Chan, MD[1]

Abstract

The hematoxylin–eosin (H&E) stain has stood the test of time as the standard stain for histologic examination of human tissues. This simple dye combination is capable of highlighting the fine structures of cells and tissues. Most cellular organelles and extracellular matrix are eosinophilic, while the nucleus, rough endoplasmic reticulum, and ribosomes are basophilic. This review discusses the spectrum, intensity, and texture of colors observed in H&E-stained slides to illustrate their value in surgical pathology diagnosis. Changes in color of the nuclei occur in the presence of nuclear pseudoinclusions (such as papillary thyroid carcinoma) or inclusions (such as viral infection, surfactant, immunoglobulin, and biotin). The color of the cytoplasm of spindly cells can provide clues to their nature, such as basophilic (fibroblast), eosinophilic (smooth muscle and others), and amphophilic (myofibroblast). Eosinophilic globules have diagnostic value for sclerosing polycystic adenosis of salivary gland, low-grade B-cell lymphoma, solid pseudopapillary tumor of pancreas, and inclusion body fibromatosis. Eosinophilic granules are characteristic of granular cells (lysosome-rich), oncocytic cells (mitochondria-rich), and cells with secretory products (including neuroendocrine cells). Eosinophilic crystals can be diagnostic of lymphoma/plasmacytoma and crystal-storing histiocytosis. Basophilic granules or inclusions are diagnostic of acinic cell carcinoma and malakoplakia (Michaelis–Gutmann bodies). Yellow or brown inclusions are characteristic of hyalinizing trabecular adenoma of thyroid (yellow bodies), brown bowel syndrome, and malignant melanoma. Extracellular eosinophilic deposits can be produced by many conditions, but amyloid and monoclonal immunoglobulin deposition disease are important considerations. Extracellular basophilic deposits may be seen in small cell carcinoma and systemic lupus erythematosus, but they differ in that the former is blue (nuclear material) while the latter is purple (nuclear material plus immunoglobulin).

Keywords

hematoxylin–eosin stain, H&E, nuclear inclusion, nuclear pseudoinclusion, eosinophilic globules, eosinophilic granules, eosinophilic crystals, basophilic granules, yellow body, extracellular matrix, Azzopardi phenomenon, hematoxylin body

Despite remarkable advances in molecular medicine capable of providing exquisite information on tumors, such as clonality, gene expression profile, genetic alterations, prognostic model, and predictive marker for response to target therapy, the microscope has remained the most important tool of the surgical pathologist in everyday practice. This is because most specimens in surgical pathology practice, such as gastrointestinal biopsies and uterine curettings, are diagnosed by histologic examination alone and do not require molecular analysis. Even for malignant neoplasms, a precise or at least a presumptive histologic diagnosis is the starting point for the selection of the relevant molecular investigations. Furthermore, examination of routine histologic sections (in addition to gross examination), coupled with immunohistochemistry, can already provide most of the crucial information for patient management.

It is extraordinary that the hematoxylin–eosin (H&E) stain, introduced more than a century ago, has stood the test of time as the standard stain for histologic examination of human tissues.[1] This simple and inexpensive dye combination is capable of revealing remarkable cellular details, to the extent that the ultrastructural features can be deduced. The interplay of colors can also provide considerable clues to the functional status of the cells. In this review, the spectrum, tone, intensity, and texture of colors observed in the H&E-stained slides are discussed to illustrate their value in diagnosis.

[1]Queen Elizabeth Hospital, Hong Kong, SAR China

Corresponding Author:
John K. C. Chan, Department of Pathology, Queen Elizabeth Hospital, Gascoigne Road, Kowloon, Hong Kong, SAR China.
Email: jkcchan@ha.org.hk

Table 1. Staining Properties of Cellular Constituents by Hematoxylin–Eosin.

Basophilic (Blue)	Eosinophilic (Pink)	No Staining (Empty)
• Nucleus (including nuclear membrane and heterochromatin) • Rough endoplasmic reticulum[a] • Ribosomes[a] • Zymogen granules of serous acinar cells in salivary gland • Catecholamine dense-core (neurosecretory) granules • Acidic mucin	• Cell membrane (including microvilli) • Cilia • Mitochondria • Lysosome • Most types of dense-core (neurosecretory) granules • Smooth endoplasmic reticulum • Intermediate filaments • Myofilaments • Microtubules • Proteins, for example, immunoglobulin, hemoglobin • Nucleolus • Neutral mucin	• Lipid vacuoles (dissolved on tissue processing)

[a]Ribosomes represent the site for synthesis of proteins to be retained in the cell for various functions, while rough endoplasmic reticulum represents the site for synthesis of proteins destined for secretion.

Hematoxylin–Eosin Staining of Normal Tissues

Staining Patterns of Normal Cells

Before discussion of the H&E staining patterns in normal tissues, a brief summary of the terms used to describe the colors is in order:

1. Basophilic: Affinity for basic dye, that is, hematoxylin. This refers to blue color.
2. Hematoxyphilic: Affinity for hematoxylin. This also refers to blue color.
3. Acidophilic: Affinity for acid dye, that is, eosin. This refers to red/pink color.
4. Eosinophilic: Affinity for eosin. This refers to red/pink color.
5. Amphophilic: Affinity for both acid and basic dyes. This refers to a purple color.

Hematoxylin itself has no staining properties, not until it has been oxidized to hematein and combined with a mordant (most commonly aluminum alum).[2] It is a positively charged (cationic) basic dye. Eosin is a negatively charged (anionic) acid dye. Sequential application of the dyes to histologic sections results in nuclei being stained blue, and cytoplasm and extracellular matrix pink.[3] In a well-stained slide, considerable intracellular details can be observed under the light microscope, reflecting the ultrastructural topographic distribution of organelles and filaments.

In the H&E stain, most cellular organelles and extracellular matrix are eosinophilic (Table 1). Some of these structures can often be appreciated by their color tone, intensity of staining, and texture, especially when present in abundance (Figure 1). For example, mitochondria appear as deep pink granules of uniform size, and filaments manifest as intracytoplasmic fibrils. Rough endoplasmic reticulum and ribosomes are basophilic, probably due to the presence of attached nucleic acids. Their abundance will impart a blue or purple color to the cytoplasm. Zymogen granules of the serous acinar cells in the salivary glands are basophilic. Cells containing intracytoplasmic acidic mucin, such as mucinous glands in mucosal sites, show light blue flocculent material in the cytoplasm.

Lipid, dissolved out of the cells by the reagents used for tissue processing, will lack staining, appearing as empty spaces. Examples are adipose cells and the finely vacuolated sebaceous cells.

Morphologic–Functional Correlation

Much information about the fine structures and functions of cells can be deduced from the H&E-stained slide. Some examples are given below.

Erythropoiesis is characterized by maturation in sequence from pronormoblasts, early normoblasts, intermediate normoblasts, late normoblasts to red blood cells. The cells belonging to the earlier stages typically have blue cytoplasm, because of presence of abundant ribosomes, which are required for synthesis of hemoglobin. As the cells mature, hemoglobin (pink color) accumulates, concurrent with gradual reduction in the amount of ribosomes. Thus the cytoplasm gradually changes from purple (ribosomes plus hemoglobin) to pink (hemoglobin plus few ribosomes; Figure 2).

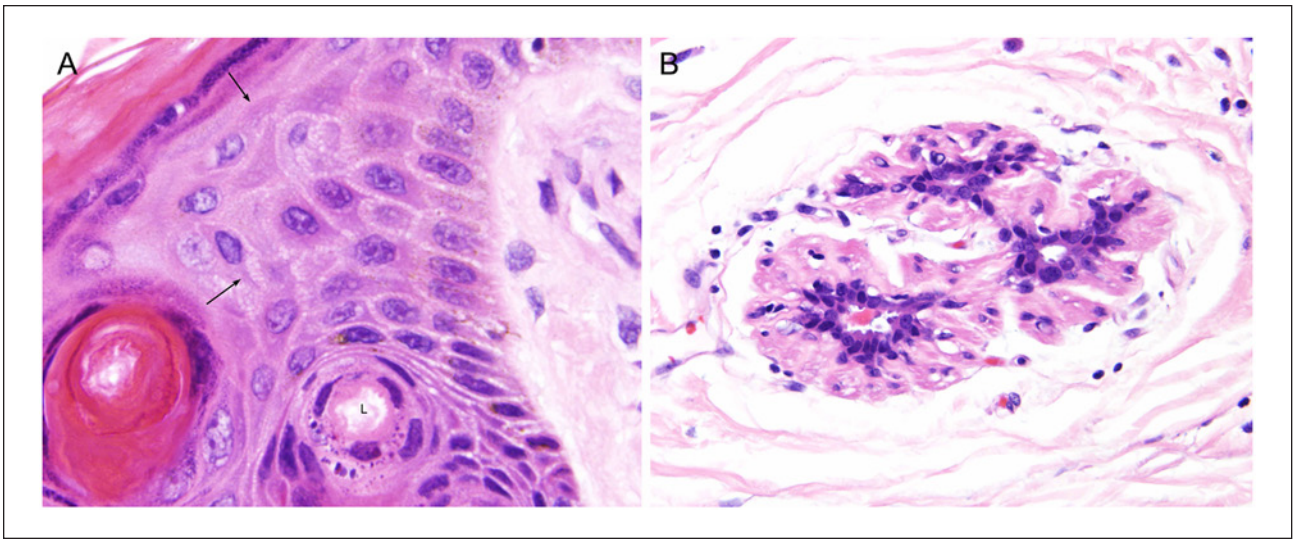

Figure 1. Colors and cellular details in hematoxylin–eosin (H&E)–stained histologic section. (A) In this skin specimen, intercellular bridges are seen between the individual squamous cells. Cytoplasmic fibrils (cytokeratin) are also evident in some cells (arrows). Note the different intensities and tones of pink staining in the different structures, from deep to light: keratin, luminal cuticle of sweat duct (L), cytoplasm of epidermal cells, and collagen. (B) A breast lobule showing myoid metaplasia of the myoepithelium. The cytoplasm of the metaplastic myoepithelium shows deep pink staining like muscle cells, being darker than the surrounding collagen fibers.

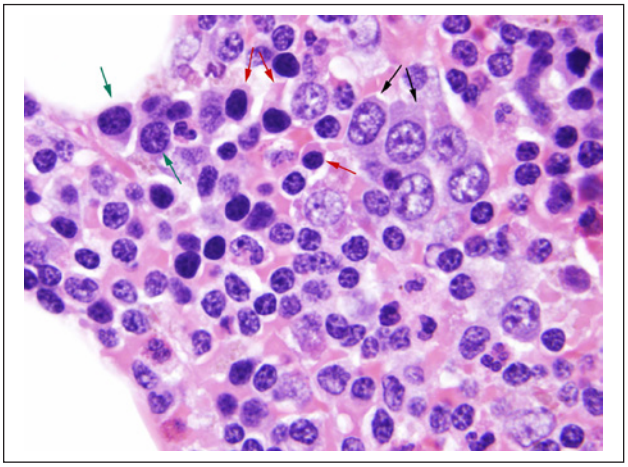

Figure 2. Bone marrow biopsy showing active erythropoiesis. Pronormoblasts and early normoblasts have basophilic cytoplasm (black arrows). Intermediate normoblasts have purple cytoplasm (green arrows). Late normoblasts have eosinophilic cytoplasm (red arrows), approaching the color of red blood cells.

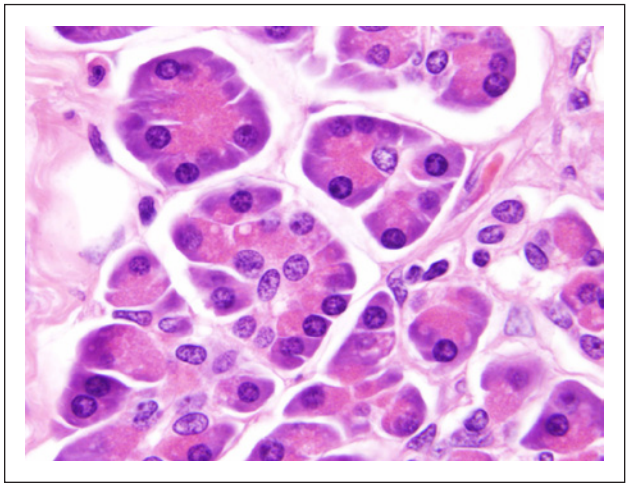

Figure 3. Pancreatic acini. The basal portion of the cells stains blue, while the upper portion shows eosinophilic granular staining.

In the pancreas, the acinar cells typically show a basophilic color in the lower half, and an eosinophilic granular appearance in the upper half (Figure 3). This pattern of coloration is expected because the lower half of the cell is rich in rough endoplasmic reticulum which is essential for synthesis of protein for secretion, and the upper half is packed with the protein products waiting to be secreted into the lumen.

In the gastric body, the parietal cells function in secretion of hydrochloric acid. The intracellular canaliculi, which can be seen on H&E staining as narrow clefts in the cytoplasm, represent the special microenvironment essential for this function (Figure 4). The eosinophilic granular cytoplasm reflects presence of abundant mitochondria, which are required to supply energy for acid secretion.

In the salivary gland, the cells lining the striated ducts have eosinophilic granular cytoplasm reflecting

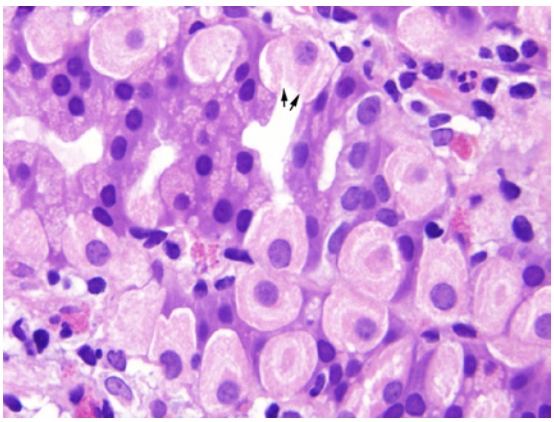

Figure 4. Gastric body mucosa: exquisite details can be appreciated in a well-stained hematoxylin–eosin (H&E) section. The narrow clefts (arrows) in the parietal cells represent intracellular canaliculi. The parietal cells have eosinophilic granular cytoplasm due to abundance of mitochondria. The chief cells seen in the left field show basophilic staining of the lower half of the cytoplasm, and eosinophilic staining with fine vacuolation in the upper half.

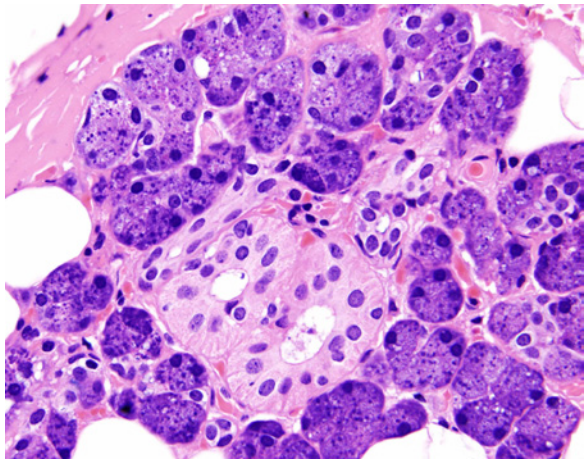

Figure 5. Parotid gland. Striated ducts (lower field) are surrounded by serous acini with basophilic granules. The striated duct epithelium shows eosinophilic granular cytoplasm with striations in the basal portion.

the presence of numerous mitochondria, which supply energy for transport of fluid and electrolytes. The basal portions of the cells show multiple streaks, because of deep infoldings of the basal cell membrane, which help increase the surface areas for fluid and electrolyte transport (Figure 5).

Aberrations in Color of Nuclear Staining

The nuclear membrane and chromatin clumps/granules typically appear basophilic in the H&E stain. The nucleolus is generally eosinophilic, but can appear amphophilic to basophilic because of the presence of overlying chromatin strands. Changes in the color of nuclei occur in the presence of nuclear pseudoinclusions or inclusions. This subject has been discussed in detail in a separate review,[4] and thus only a summary is presented (Table 2).

Nuclear Pseudoinclusions: Diagnostic Value

Nuclear pseudoinclusions, although not specific or pathognomonic of any disease entity, is a characteristic finding in papillary thyroid carcinoma, hyalinizing trabecular adenoma of the thyroid, meningioma, and usual ductal hyperplasia of the breast (Figure 6). The presence of readily identifiable nuclear pseudoinclusions favors these diagnoses over their mimickers (Table 2).

Nuclear Inclusions: Diagnostic Value and Pitfall

Nuclear inclusions, when present, are diagnostically helpful. The different appearances of the viral inclusions, in combination with the clinical scenario, cell type being involved and host reaction, can provide important clues to the type of virus. Readily identifiable Dutcher bodies in a lymphoplasmacytic or plasmacytic infiltrate provide an important clue for the neoplastic nature of the cellular proliferation (Figure 7). In an adenocarcinoma, the presence of nuclear inclusions is highly suggestive of a pulmonary origin because the inclusions represent inspissated surfactant (Figure 8). On the other hand, nuclear inclusions can be misleading to the unwary, such as biotin inclusions, which can be mistaken for viral inclusions (Figure 9).

Colors and Aberrations of Cytoplasmic Staining as Clues to Diagnosis

Clue to Diagnosis From Cytoplasmic Color

In the assessment of mesenchymal cell proliferations, determining the direction of differentiation of the cells is an important first step toward arriving at a diagnosis. The color of the cytoplasm often provides an important clue on the nature of the spindly (sometimes oval) cells (Figure 10). Fibroblasts have abundant rough endoplasmic reticulum essential for protein (collagen) synthesis; thus the cytoplasm is blue on H&E staining (Figure 11A). Smooth muscle and skeletal muscle cells are packed with myofilaments and intermediate filaments (vimentin) in the

Table 2. Nuclear Pseudoinclusions and Inclusions.

Type of Nuclear Pseudoinclusion or Inclusion	Morphology	Occurrence and Significance
Nuclear pseudoinclusion		
Nuclear pseudoinclusion formed by invagination of cytoplasm into nucleus	Nuclear pseudoinclusion is bound by basophilic nuclear membrane, and contains eosinophilic cytoplasmic material	Common occurrence in: • Usual ductal hyperplasia of breast (of value for distinction from low-grade intraductal carcinoma) • Papillary thyroid carcinoma (of value in differential diagnosis from other thyroid tumor types, except hyalinizing trabecular adenoma) • Hyalinizing trabecular adenoma of thyroid • Meningioma (of value in differential diagnosis from schwannoma, particularly at intraoperative diagnosis)
Nuclear inclusion		
Viral inclusion	Two major morphologic patterns: 1. Replacement of the entire nucleus by homogeneous lightly to deeply amphophilic material, sometimes imparting a ground-glass quality 2. Large discrete eosinophilic or amphophilic inclusion body, often surrounded by halo (can sometimes be difficult to distinguish from nucleolus)	Some, but not all, viruses produce nuclear inclusions observable on light microscopy. Examples are cytomegalovirus, herpes simplex virus, human herpesvirus 6, adenovirus, parvovirus B19, measles, JC virus, and BK virus. The identity of the virus can often be determined from the clinical setting, site of disease, type of infected cell and morphology of the viral inclusion-containing cells (such as nuclear enlargement, presence of cytoplasmic inclusions, multinucleation), and preferably confirmed by immunohistochemistry, electron microscopy or molecular studies
Glycogen	Nucleus show enlargement and clearing, with lightly eosinophilic flocculent to homogeneous material in the central portion	Glycogenated nuclei are common in, but not limited to, the liver of patients with obesity, diabetes, nonalcoholic fatty liver disease, Wilson disease, and amiodarone toxicity
Biotin	Nuclear matrix completely replaced by lightly eosinophilic, homogeneous, ground-glass material	Common in epithelial cells of gestational endometrium: can potentially be mistaken for viral inclusions (such as herpes endometritis) A characteristic finding in several tumor types, mainly those with morule formation, for example, cribriform-morular variant of papillary thyroid carcinoma, pancreatoblastoma, pulmonary blastoma, fetal-type pulmonary adenocarcinoma
Immunoglobulin (Dutcher body)	Brightly eosinophilic homogeneous material within nucleus, often solitary, but occasionally multiple, predominantly in plasma cells	Dutcher bodies are often prominent in lymphoplasmacytic lymphoma, and can be variably present in marginal zone lymphoma and plasmacytic neoplasms. Readily found Dutcher bodies in a plasmacytic or lymphoplasmacytic infiltrate is highly suggestive of a monoclonal/neoplastic process, a diagnosis easily confirmed by demonstration of immunoglobulin light chain restriction
Surfactant	Single or multiple lightly eosinophilic homogeneous material within nucleus of epithelial cell	A hallmark of pneumocytes when present—seen in reactive pneumocytes (rare), sclerosing hemangioma (rare) and pulmonary adenocarcinoma. Helpful for suggesting the pulmonary origin of an adenocarcinoma
Nuclear lamins (Marinesco bodies)	Lightly eosinophilic inclusions in neurons	Incidental finding of no significance
Polyglutamine	Eosinophilic hyaline intranuclear inclusions in neurons	Neurodegenerative diseases, such as Huntington chorea, Kennedy disease, and spinocerebellar ataxia

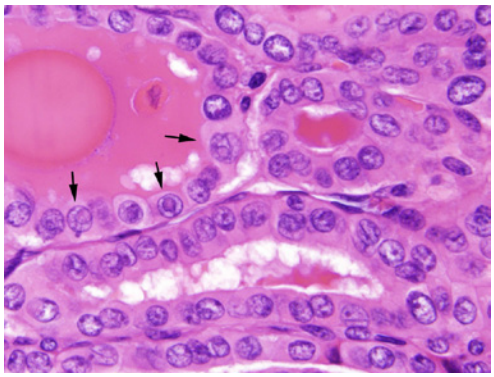

Figure 6. In this encapsulated follicular-patterned tumor of the thyroid, the presence of readily identified nuclear pseudoinclusions (arrows) represents one of several morphologic features supporting a diagnosis of papillary carcinoma (follicular variant).

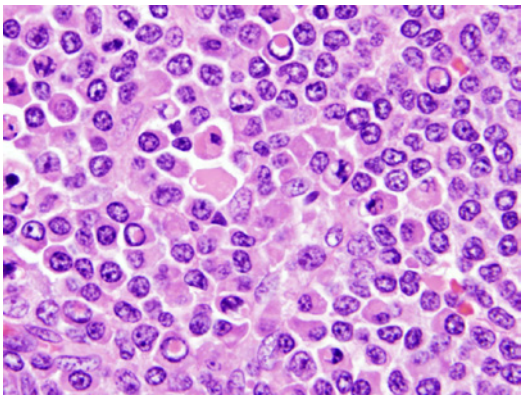

Figure 7. Lymphoplasmacytic lymphoma rich in Dutcher bodies (intranuclear eosinophilic inclusions). Presence of readily found Dutcher bodies in a lymphoplasmacytic or plasmacytic infiltration is a feature highly suggestive of a neoplastic process.

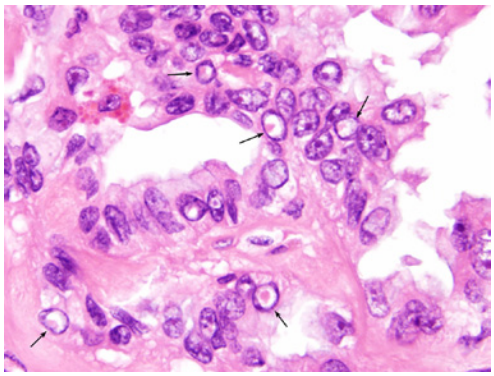

Figure 8. Pulmonary adenocarcinoma with intranuclear surfactant inclusions (arrows). The inclusions stain a lighter color than the nucleoli.

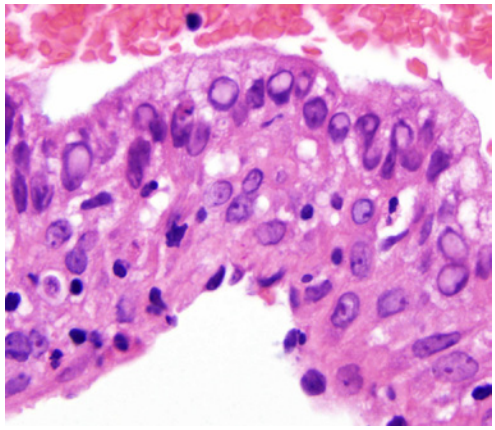

Figure 9. Gestational endometrium with biotin inclusions in some epithelial cells.

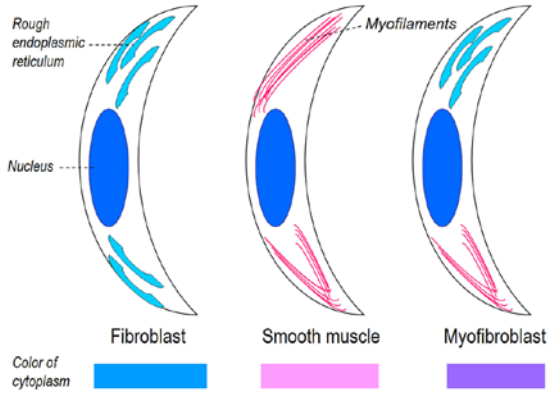

Figure 10. Schematic drawing to show correlation of ultrastructure with hematoxylin–eosin (H&E) staining for fibroblast, smooth muscle cell, and myofibroblast. Fibroblast is rich in rough endoplasmic reticulum, and the cytoplasm stains blue. Smooth muscle cell is rich in myofilaments, and the cytoplasm staining deep pink. Myofibroblast is rich in both rough endoplasmic reticulum and myofilaments, and thus stains purple.

cytoplasm, which should appear deep pink; sometimes a fibrillary quality can also be appreciated (Figure 11B). Myofibroblasts, which are hybrids of smooth muscle cells and fibroblasts, contain both rough endoplasmic reticulum (blue staining) and myofilaments (pink staining), and thus typically have purple-staining cytoplasm (Figure 11C). Therefore, for lesions composed of genuine myofibroblasts, such as nodular fasciitis and related lesions, desmoid fibromatosis, inflammatory myofibroblastic tumor, and myofibroblastic sarcoma, the cytoplasm of the proliferated cells should be amphophilic (Figure 12). Some soft tissue tumor entities apparently implicate myofibroblastic differentiation in their terminology, such as mammary

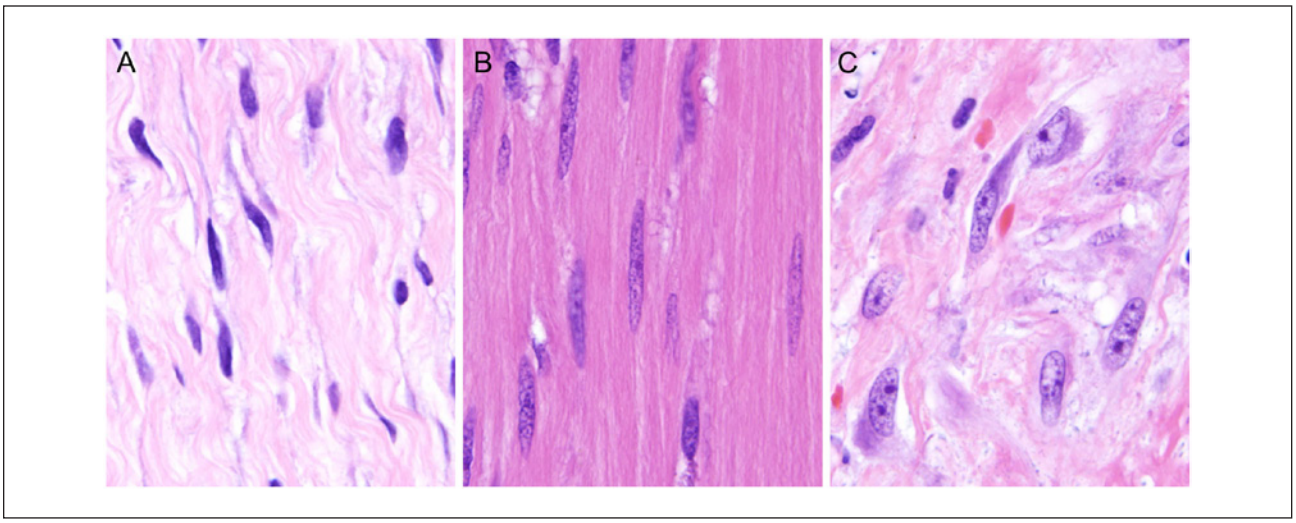

Figure 11. Hematoxylin–eosin (H&E) staining of fibroblast, smooth muscle, and myofibroblast. (A) Fibroblasts with slender cell bodies that stain blue. The nuclei are often dark staining. (B) Smooth muscle cells have deeply eosinophilic cytoplasm with fibrillary quality. (C) Myofibroblast found in granulation tissue. The cytoplasm is purple, and the nuclei are typically active looking.

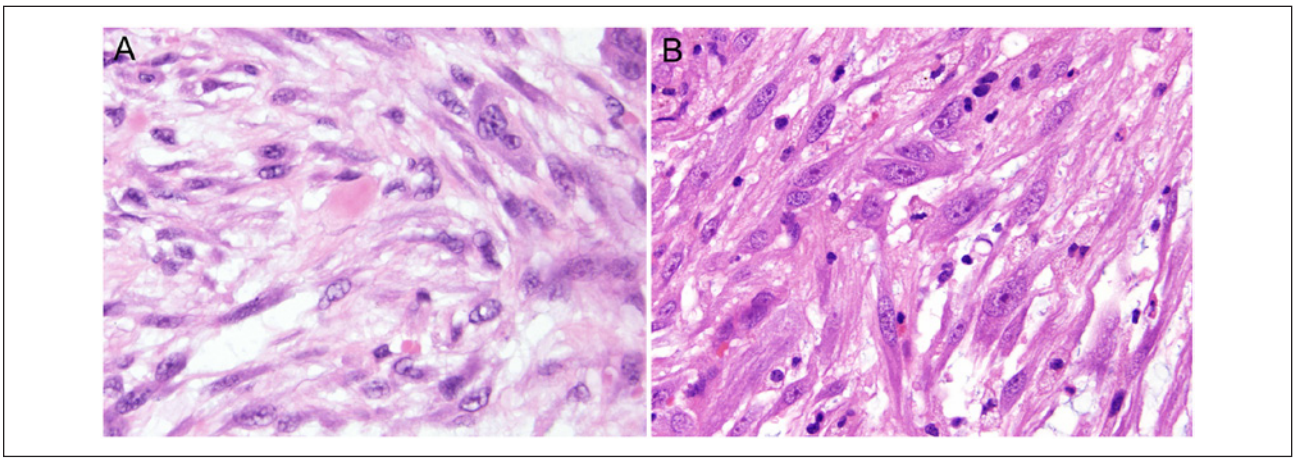

Figure 12. Myofibroblastic lesions, characterized by amphophilic (purple) cytoplasm in the lesional cells. (A) Nodular fasciitis. (B) Inflammatory myofibroblastic tumor.

myofibroblastoma, infantile myofibromatosis, and angiomyofibroblastoma, but the lesional cells have eosinophilic cytoplasm. Either these terms are misnomers, or the cells represent nonconventional subsets of myofibroblastic cells. Smooth muscle tumor cells should have deeply eosinophilic cytoplasm, with or without a fibrillary quality, and the outlines of the individual cells are often discernible because there are no interdigitating cell processes (Figure 13).

Among hematolymphoid neoplasms, lymphomas usually show amphophilic to basophilic cytoplasm, while histiocytic and dendritic cell tumors typically show eosinophilic cytoplasm. Thus the cytoplasmic color of the neoplastic cells can provide important clues to their nature, directing the appropriate studies to confirm the diagnosis (Figure 14).

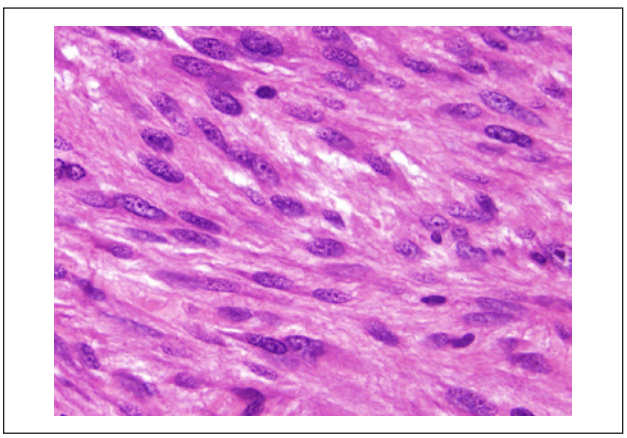

Figure 13. Leiomyosarcoma of soft tissue. Note the eosinophilic cytoplasm with fibrillary quality. Cell borders are distinct.

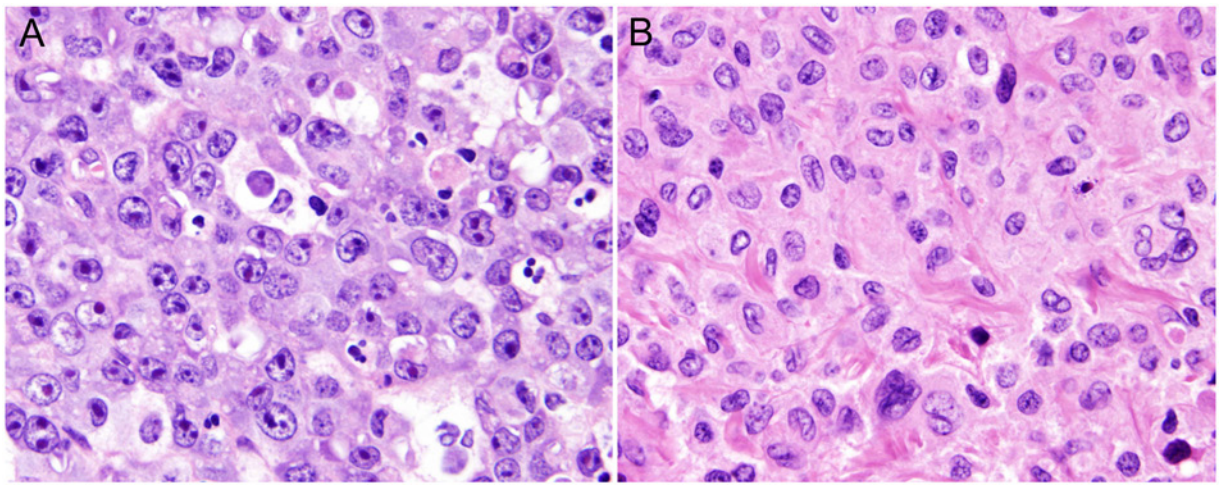

Figure 14. Color of cytoplasm in hematolymphoid neoplasms. (A) Anaplastic large cell lymphoma, with abundant purple cytoplasm. (B) Dendritic cell tumor, typically with eosinophilic cytoplasm.

Plasma cells normally have basophilic to amphophilic cytoplasm. The presence eosinophilic cytoplasm in a high proportion of cells is suspicious for a neoplastic/monoclonal process because that indicates similar "constipation" with synthesized immunoglobulin (pink) in most cells.

Minimal deviation adenocarcinoma of the uterine cervix usually shows a gastric phenotype, resembling foveolar epithelium of the stomach in that the mucin is of neutral type, appearing pink in H&E stain. Thus the color of the cytoplasm can provide an important clue to the diagnosis, because normal endocervical epithelial cells contain a mixture of acidic and neutral mucins, and thus show blue-staining intracytoplasmic mucin.[5]

Clue to Diagnosis From Granules and Inclusions in Cytoplasm

Eosinophilic Globules. Eosinophilic globules, which can result from many different mechanisms, can potentially provide important clues to diagnosis. Although their nature is known for some, it remains elusive for others.

In a salivary gland lesion showing brilliantly eosinophilic globules in the cytoplasm of some glandular structures, *sclerosing polycystic adenosis* has to be seriously considered (Figure 15). This is because such eye-catching granules are practically never seen in other salivary gland entities, but are virtually always found in sclerosing polycystic adenosis.[6]

In a plasmacytic or lymphoplasmacytic proliferation in which a high proportion of cells contain brightly eosinophilic globules (immunoglobulin), also known as *Russell bodies*, a monoclonal, and hence neoplastic, process should be strongly suspected (Figure 16). Isolated cells containing Russell bodies have no significance, but when many cells show an identical "aberrant" morphology, that suggests their derivation from the same clone.[5]

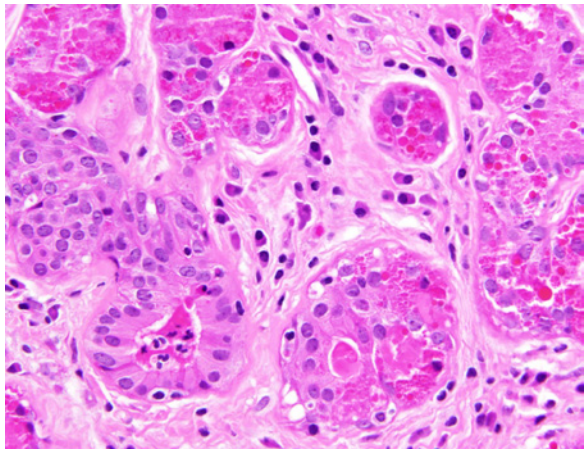

Figure 15. Sclerosing polycystic adenosis of parotid gland. Typically there are some small glandular structures with abundant brilliantly eosinophilic large globules.

Eosinophilic hyaline globules are commonly found in some tumor types, such as yolk sac tumor, solid-pseudopapillary tumor of pancreas, Kaposi sarcoma, and pheochromocytoma. They are often present in the form of multiple globules within a tumor cell. Their presence may aid in diagnosis in the appropriate setting, such as diagnosis

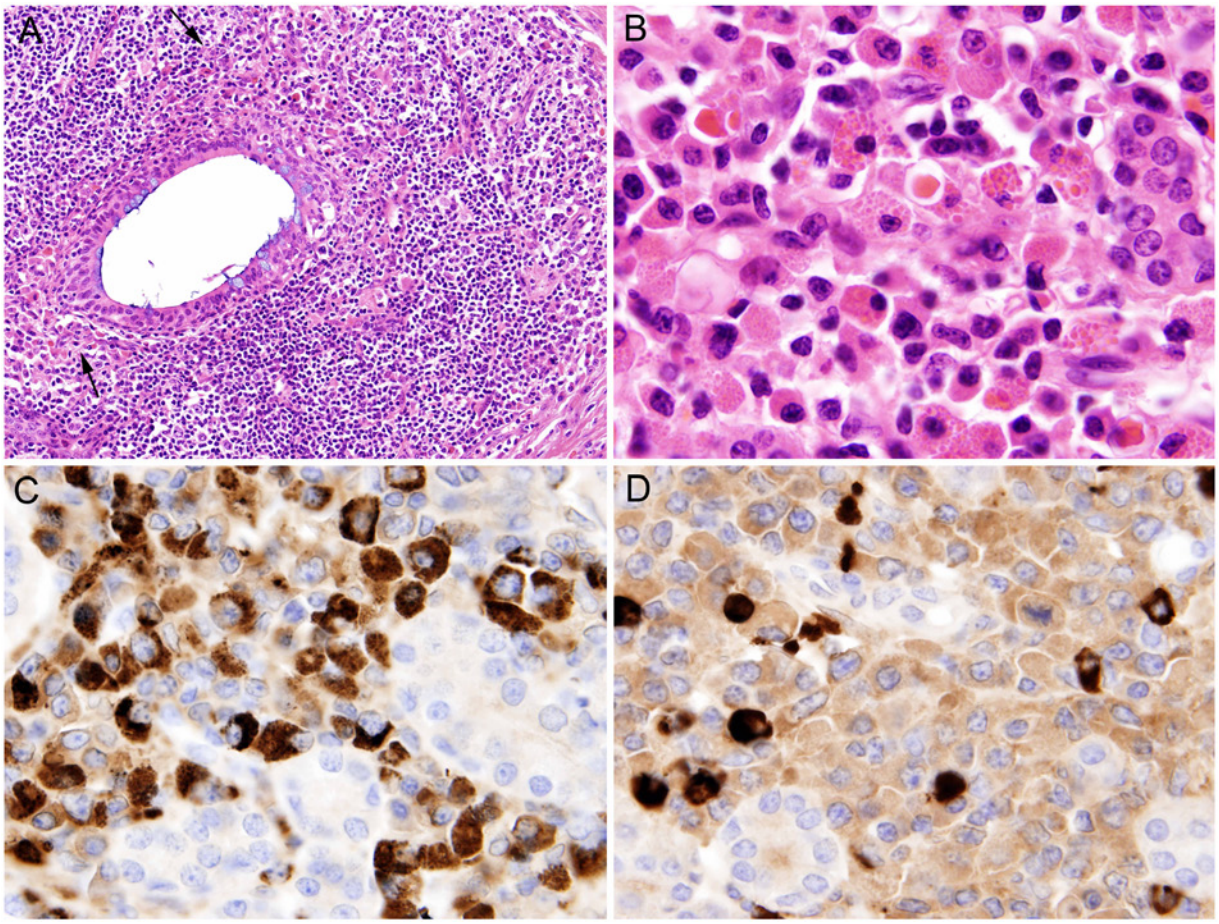

Figure 16. Kuttner tumor of submandibular gland with focal supervening low-grade B-cell lymphoma. (A) In the inflammatory background, there are foci with aggregates of abnormal plasma cells (arrows). (B) The plasma cells contain abundant eosinophilic globules. (C) The globule-containing plasma cells are immunoreactive for kappa light chain. (B) The globule-containing plasma cells are not immunoreactive for lambda light chain. The faint brown staining seen in this figure is nonspecific.

of early Kaposi sarcoma, which may manifest deceptively as a mere mild increase of spindle cells in lymph node capsule, and diagnosis of solid-pseudopapillary tumor of pancreas, for which the histologic features are otherwise nondescript (Figure 17). The presence of solitary deeply eosinophilic globule, often located close to the nucleus of the proliferated myofibroblastic cells, is a diagnostic feature of inclusion body fibromatosis.

Rare types of eosinophilic globules have internal structures, allowing definitive recognition of their nature. *Spironolactone bodies*, which develop in the normal zona glomerulosa cells of the adrenal gland or in aldosterone-producing adrenal cortical neoplasms following treatment with the aldosterone antagonist spironolactone, are eosinophilic inclusions with a laminated, scroll-like appearance (Figure 18).[7] The laminated appearance is related to the abundance of phospholipids with formation of concentric membranes ultrastructurally.

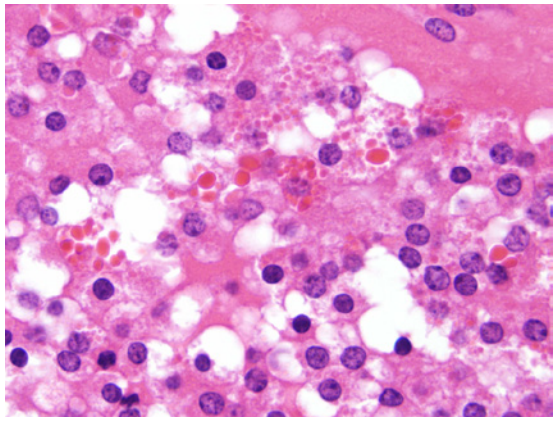

Figure 17. Solid-pseudopapillary tumor of pancreas. The morphology is rather nondescript, but hyaline globules are commonly present.

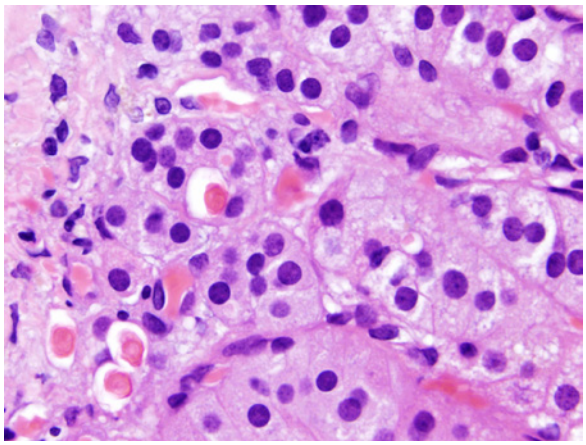

Figure 18. Adrenal gland with hyperplasia of zona glomerulosa. The cells in the left lower field contain spironolactone bodies, which are eosinophilic structures with a laminated architecture.

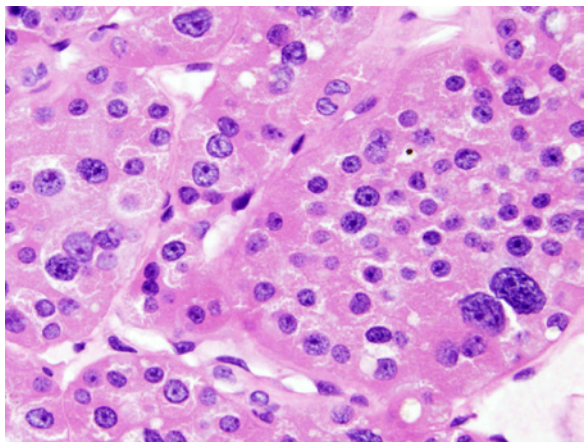

Figure 20. Oncocytoma of kidney. The cells show densely granular cytoplasm characteristic of mitochondria-rich tumor cells. Like oncocytomas of other anatomic sites, the nuclei show distinct nucleoli and there is a rich vascularity (often with a sinusoidal quality).

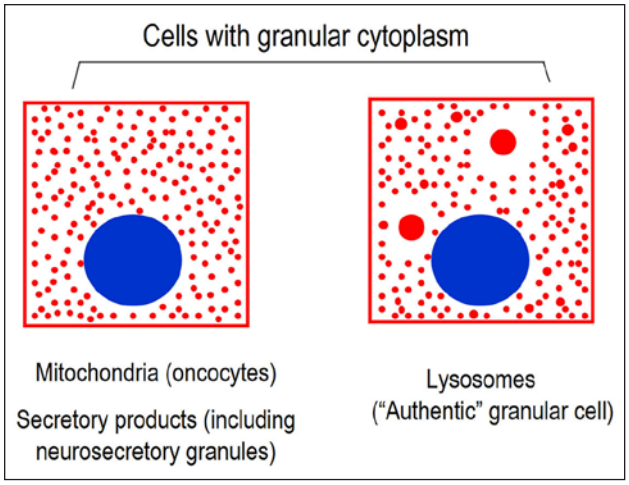

Figure 19. Schematic drawing to depict the different nature of cells with granular cytoplasm.

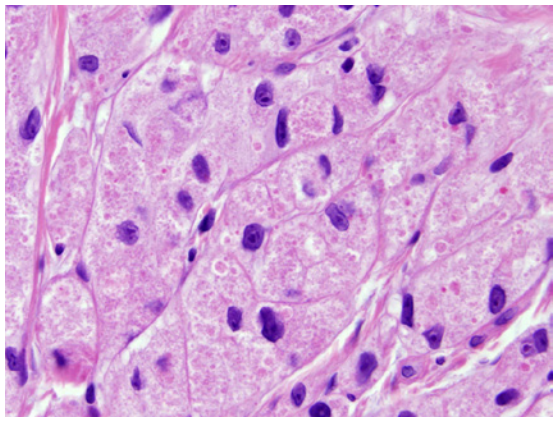

Figure 21. Granular cell tumor of skin. There are packets of large polygonal cells with intracytoplasmic eosinophilic granules. Occasional granules are larger and surrounded by haloes.

Eosinophilic Granular Cytoplasm. Cells can be rich in eosinophilic granules due to accumulation of organelles or secretory products. They include oncocytes (rich in mitochondria), "authentic" granular cells (rich in lysosomes), neuroendocrine cells (rich in neurosecretory granules), and cells rich in secretory granules or products (such as apocrine cells, Paneth cells, stromal granulocytes in endometrium, myeloid cells; Figure 19).

Oncocytic cells are polygonal cells with eosinophilic, densely granular cytoplasm; the nuclei often show distinct nucleoli. Oncocytic neoplasms, which comprise exclusively oncocytic cells, can occur in diverse sites, such as the thyroid (Hurthle cell neoplasm), parathyroid, kidney, and salivary gland (Figure 20). Irrespective of the site of origin, they almost always show a prominent delicate vasculature. In addition, oncocytic change can occur focally or extensively in many tumor types as a morphologic variant, such as follicular adenoma of thyroid, parathyroid adenoma, carcinoid tumor, and mucoepidermoid carcinoma.

In "authentic" *granular cells*, larger granules surrounded by haloes are typically interspersed among small eosinophilic granules (Figure 21). Since the granules represent lysosomes, they are immunoreactive for histiocytic markers targeting lysosomal proteins, such as CD68.[8] Granular cells do not occur normally, but represent the morphologic

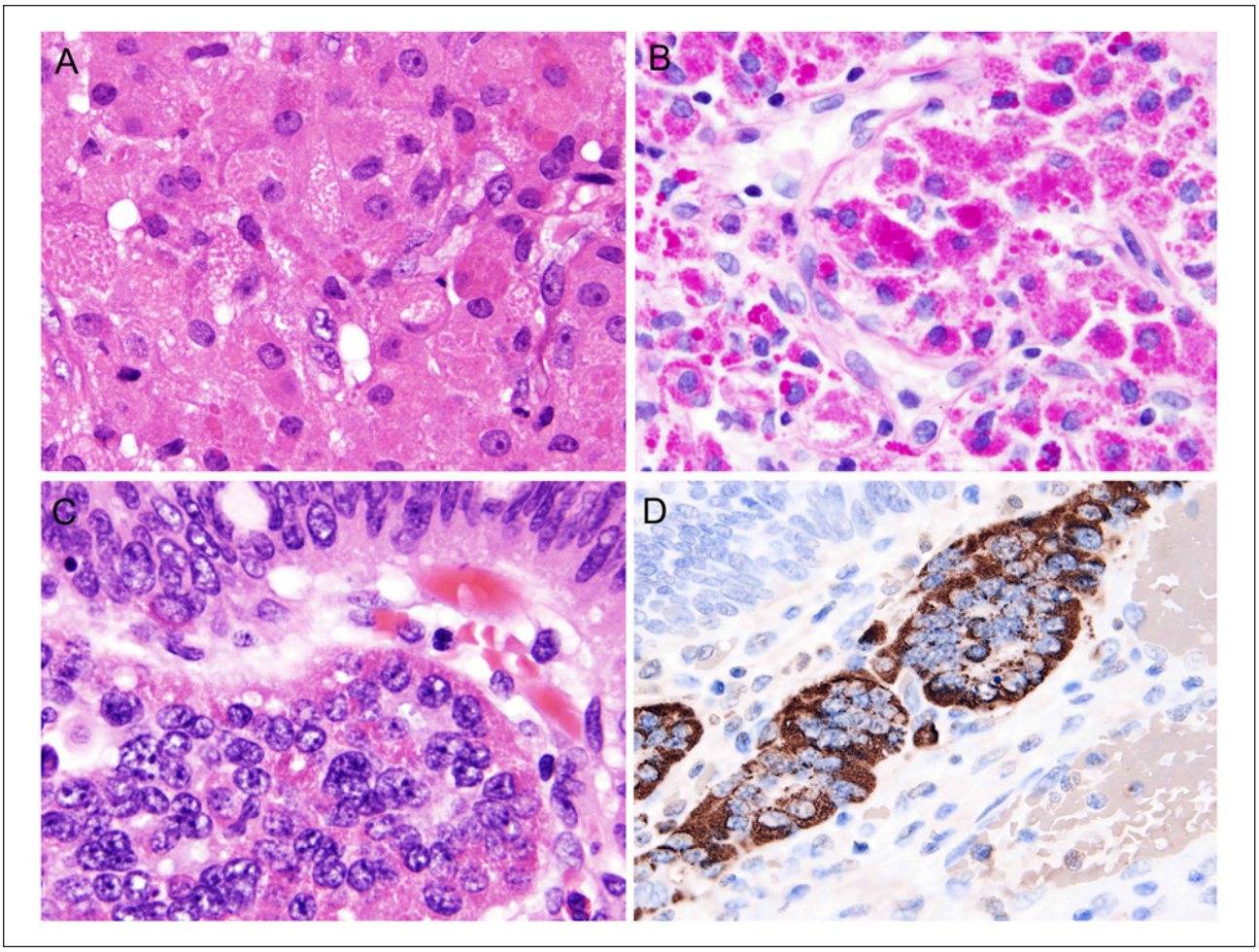

Figure 22. Intracytoplasmic eosinophilic granules. (A) Granular cell reaction. The granular cells are histiocytes and do not show a packeting growth pattern as in granular cell tumor. (B) A corresponding slide stained with periodic acid Schiff (PAS)–diastase, with variable-sized granules being well highlighted. (C) Neuroendocrine tumor of bile duct. The tumor cells have abundant brightly eosinophilic granules, mostly polarized toward the fibrovascular septa, supporting the neuroendocrine nature of the tumor. (D) In a corresponding slide immunostained for chromogranin, the distribution of the granules toward the vascular poles of the cells is more obvious.

manifestation of pathologic changes in diverse cell types. The diagnosis of lesions rich in granular cells therefore rests on consideration of the clinical, histologic and/or immunohistochemical findings. *Granular cell tumor* (not otherwise specified) are tumors with diffuse granular cell change throughout and exhibit features of Schwann cell differentiation on immunohistochemical (S100+) and ultrastructural examination (Figure 21). *Congenital granular cell epulis* occurs in the oral cavity of newborns or infants, and is morphologically very similar to granular cell tumor, except for lack of hyperplasia of overlying epithelium, frequent presence of remnant odontogenic epithelium and higher vascularity, and lack of S100 protein immunoreactivity.[9,10] *Primitive polypoid nonneural granular cell tumor* occurs in the skin of children or adults. It differs from granular cell tumor in its circumscription, presence of some degree of nuclear pleomorphism and mitotic activity, absence of pseudoepitheliomatous hyperplasia, and lack of S100 immunoreactivity.[11-13] Various *specific tumor types* can also show focal to extensive granular cell change, such as ameloblastoma, leiomyoma, leiomyosarcoma, dermatofibroma, fibrous histiocytoma, dermatofibrosarcoma protuberans, angiosarcoma, and basal cell carcinoma.[9,14-21] The nongranular areas basically look like their conventional counterpart and thus the diagnosis should be based on these areas. *Granular cell reaction* is a reactive process characterized by aggregates of histiocytes with granular cytoplasm.[22-26] It can be associated with prior trauma, tissue injury, or nearby prosthesis. The morphology simulates that of granular cell tumor except for smaller nuclei, lack of formation of nests and cords, presence of wear debris in cytoplasm, and S100 protein negativity (Figure 22A).

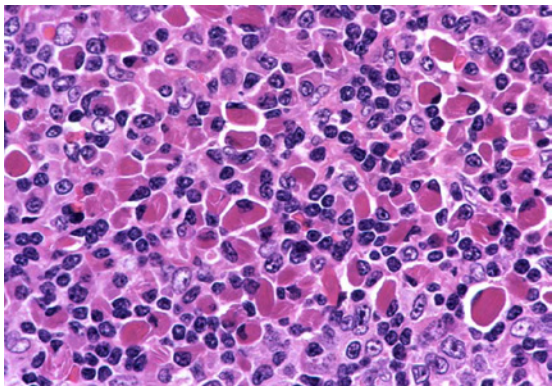

Figure 23. Lymphoplasmacytic lymphoma with crystalline inclusions (immunoglobulin) in the cytoplasm of the lymphoma cells.

Neuroendocrine cells normally show finely granular cytoplasm, but some endocrine cells may have larger and more brightly eosinophilic granules. When eosinophilic granules are found to be polarized toward the vascular pole of the cell, this is a strong indication that the granules are neuroendocrine in nature (Figure 22B). Neuroendocrine tumors (such as carcinoid and paraganglioma) retain similar cytoplasmic granular characteristics.

In the prostate, there can be cells with deeply eosinophilic granules, reminiscent of Paneth cells. Such *Paneth cell–like cells* are neuroendocrine cells that occur as a focal or extensive component of prostatic carcinoma. The importance of their recognition is that such areas of the tumor should not be included for Gleason scoring, otherwise over-grading will result.[27]

Eosinophilic Crystals in Cytoplasm. When intracytoplasmic crystals are readily identified in a significant proportion of cells in a plasmacytic or lymphoplasmacytic proliferation, a monoclonal process has to be strongly suspected (Figure 23). The crystals are brightly eosinophilic needle-shaped or elongated rhomboid-shaped, and represent crystallized immunoglobulin. The consistent "aberrant" appearance of the cells suggests their derivation from the same clone. Immunoglobulin light chain restriction can usually be readily demonstrated on immunostaining, and hence a diagnosis of plasmacytoma or low-grade B-cell lymphoma.[5]

Massive accumulation of eosinophilic needle-shaped crystals in spindly, rounded or angulated histiocytes is characteristic of *crystal-storing histiocytosis* (Figure 24).[28] This condition differs from that discussed in the preceding paragraph in that the cells have much more voluminous cytoplasm, and are histiocytes (CD68+, CD163+) rather than B lymphocytes or plasma cells. It can potentially be misdiagnosed as rhabdomyoma. In the great majority of cases, the crystals represent crystallized immunoglobulin ingested by histiocytes. The diagnosis should prompt careful investigation for presence of clonal hematologic disease (90% of cases), most commonly plasma cell disorders (myeloma, plasmacytoma, monoclonal gammopathy of uncertain significance), extranodal marginal zone lymphoma, and lymphoplasmacytic lymphoma.[28-32] Rare cases of crystal-storing histiocytosis are caused by accumulation of Charcot–Leyden crystals, which are brightly eosinophilic, and the clue to diagnosis is the presence of numerous admixed eosinophils.[33] Exceptional cases are caused by accumulation of clofazimine, a drug used for treating leprosy, but the crystals (having been dissolved in alcohol during tissue processing) appear clear rather than eosinophilic in H&E-stained section, and red with red birefringence in frozen section.[34]

Thick rod-shaped eosinophilic crystals (*Reinke crystalloids*) are characteristic of the normal Leydig cells of the testis, but they are only sometimes found in Leydig cell tumors of the testis and ovary.

Basophilic Granules, Globules, or Inclusions: Uncommon Occurrence. Basophilic intracytoplasmic granules, globules or inclusions, in contrast to eosinophilic ones, are uncommon. They can be of diagnostic value.

Among salivary gland tumors, there is extensive morphologic overlap between *acinic cell carcinoma* and mammary analogue secretory carcinoma.[35,36] Identification of basophilic zymogen granules in the tumor cells, albeit focally, renders a diagnosis of acinic cell carcinoma definitive, and excludes mammary analogue secretory carcinoma (Figure 25).[37] Nonetheless, failure to identify basophilic zymogen granules does not totally rule out acinic cell carcinoma.

There are several types of intracellular basophilic, calcium-containing inclusions. *Michaelis–Gutmann bodies* are round, concentrically layered basophilic inclusions (representing remnants of phagolysosomes encrusted with calcium) which constitute an essential diagnostic criterion of malakoplakia (Figure 26).[38] *Schaumann bodies* are basophilic inclusions occurring in multinucleated histiocytes of granulomas of diverse etiologies, such as sarcoidosis, hypersensitivity pneumonitis, and berylliosis.[39,40] They are lamellated, shell-like (conchoidal) bodies, often irregular in shape, with calcium oxalate crystals in the center.

In a cell containing intranuclear viral inclusion, the presence of coarse basophilic to amphophilic granules (inclusions) in the cytoplasm is diagnostic of *cytomegalovirus* infection versus other types of viruses (Figure 27).

Neural and neuroendocrine tumors usually have eosinophilic granular cytoplasm due to the abundance of neurosecretory granules. *Pheochromocytoma and related sympathetic paragangliomas*, on the other hand, often have basophilic or amphophilic cytoplasmic granules instead (Figure 28).

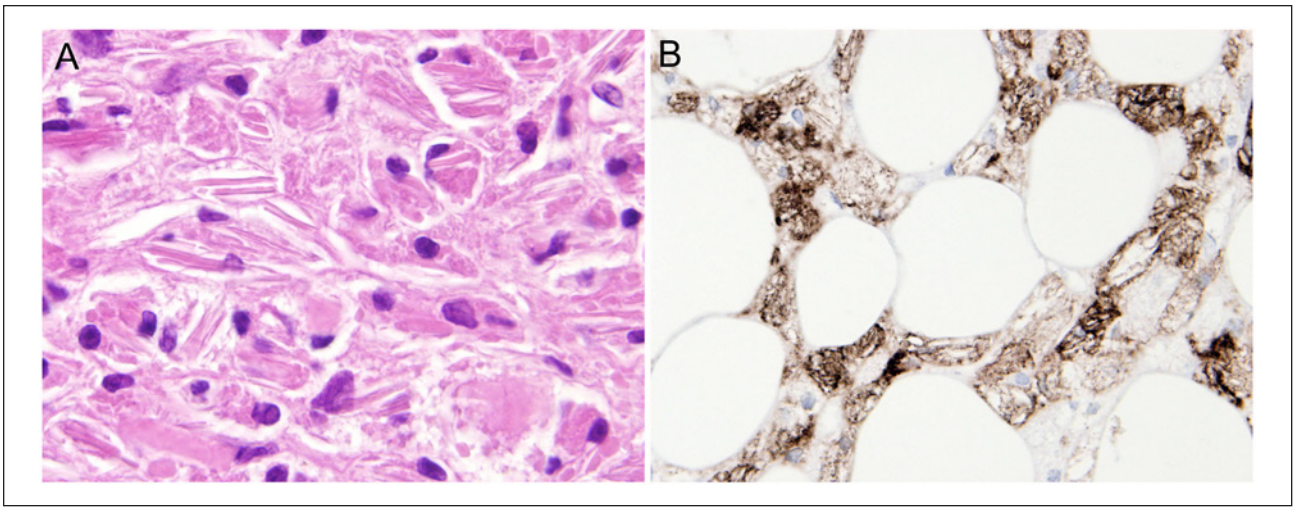

Figure 24. Crystal storing histiocytosis. (A) The histiocytes contain abundant eosinophilic elongated crystals. (B) The histiocytes are immunoreactive for the histiocytic marker CD163.

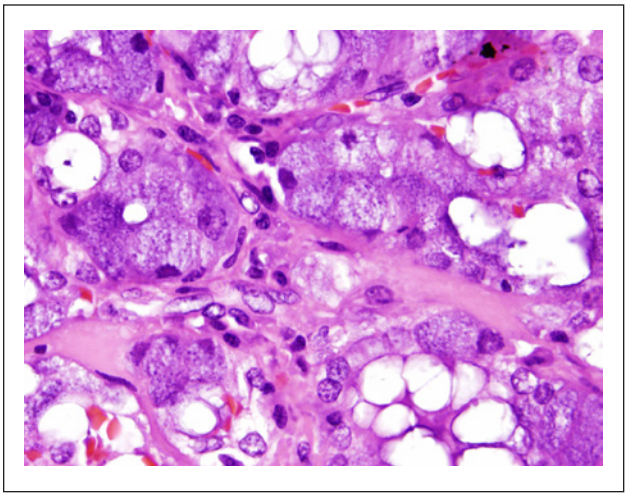

Figure 25. Acinic cell carcinoma. In this tumor, basophilic granules are definitely found focally, thus supporting a diagnosis of acinic cell carcinoma.

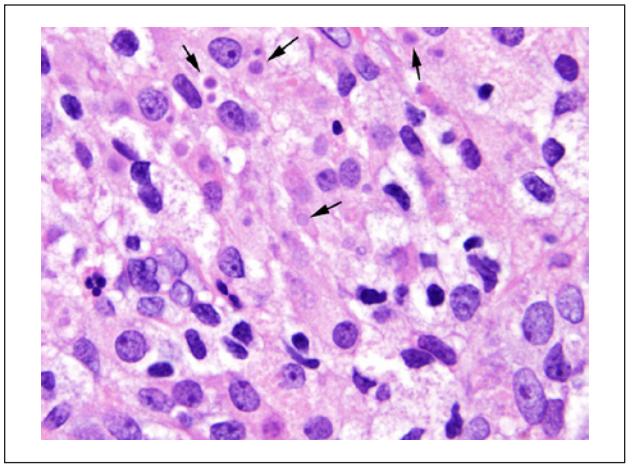

Figure 26. Malakoplakia. The histiocytes have eosinophilic granular cytoplasm. Some of them contain basophilic Michaelis–Gutmann bodies (arrows). In this example, the usual laminated architecture of Michaelis–Gutmann bodies is not evident.

A remarkable type of blue-staining inclusion in tumor cell is the *intracytoplasmic lumen* (intracytoplasmic vacuole). It appears as a single or sometimes multiple sharply delineated round structure with a blue-staining rim (formed by cell membrane) and central pink-staining mucinous material surrounded by a halo (Figure 29). Thus it is very different from the more commonly encountered intracytoplasmic mucin. In fact, it represents a "private lumen" in a "single-cell gland." Staining with Alcian blue/periodic acid Schiff (PAS) will reveal a striking bull's-eye (target) appearance, because of presence of acidic mucin associated with the membrane of the intracytoplasmic lumen (stained blue by Alcian blue), and neutral mucin in the center (stained deep pink by PAS). Intracytoplasmic lumens are a characteristic though not pathognomonic feature of lobular carcinoma of breast, to the extent that they can be useful in predicting the breast origin for adenocarcinoma of unknown primary.[41] They can sometimes also be seen in ductal carcinoma of the breast, adenocarcinoma of stomach and clear cell carcinoma of the ovary.

Intracellular Yellow or Brown Materials. Intracellular yellow or brown materials may include bile, hemosiderin, melanin pigment, lipofuscin, yellow bodies, and fungus (such as chromoblastomycosis). Their identification requires assessment of the color, texture, and context, and may be aided by special studies.

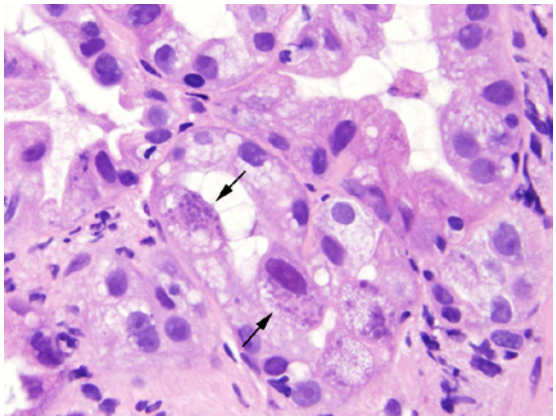

Figure 27. Gastric mucosa with cytomegalovirus infection. Basophilic granular inclusions are seen in the infected cells (arrows). In the upper cell, the nucleus is not seen in this plane of sectioning.

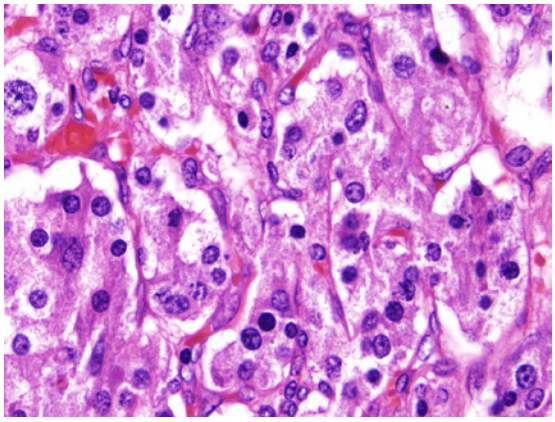

Figure 28. Pheochromocytoma. Note the basophilic granules in the cytoplasm.

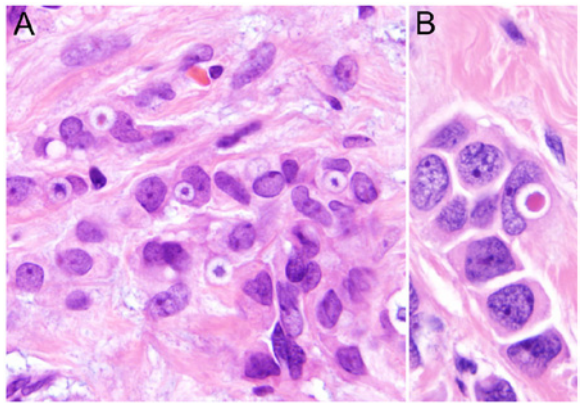

Figure 29. Intracytoplasmic lumens in lobular carcinoma of breast. (A) In the cytoplasm of the tumor cells, there are discrete vacuoles with a blue rim and pink material in the center, resulting in a targetoid appearance. Sometimes the centrally located pink-staining mucin is overshadowed by blue-staining mucin in the lumen. (B) Another example in which the intracytoplasmic lumen shows prominent eosinophilic mucin in the center, while the basophilic rim is less striking.

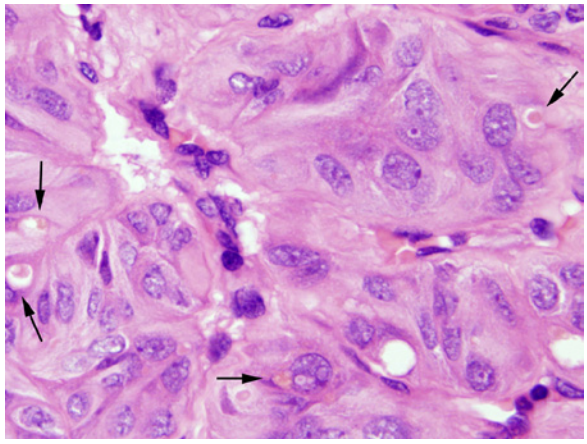

Figure 30. Hyalinizing trabecular adenoma of thyroid. Yellow bodies are indicated by arrows.

Yellow bodies are peculiar intracytoplasmic inclusion bodies occurring consistently in abundance in hyalinizing trabecular adenoma of the thyroid. They are round, pale yellow and refractile, often with a granular substructure (Figure 30). They represent giant lysosomes.[42] Although yellow bodies may be present in papillary carcinoma and follicular neoplasm, they are uncommon and present only focally.[43]

Lipofuscins are yellow-brown to reddish-brown pigments representing the end-stage oxidation products of lipids and lipoproteins. Oxidation process occurs slowly and progressively, and thus the pigments exhibit a range of colors and variable staining reactions. Lipofuscins are a common occurrence in many cell types, such as heart muscle cells and hepatocytes. In some disease entities, they occur in abundance and constitute an essential feature for diagnosis, such as brown bowel syndrome and primary pigmented nodular adrenal cortical hyperplasia.

Melanin, when present within tumor cells, generally indicates a diagnosis of nevus or melanoma, although other tumor types can sometimes be pigmented, such as dermatofibrosarcoma protuberans, clear cell sarcoma, renal cell carcinoma, and psammomatous melanotic schwannoma.

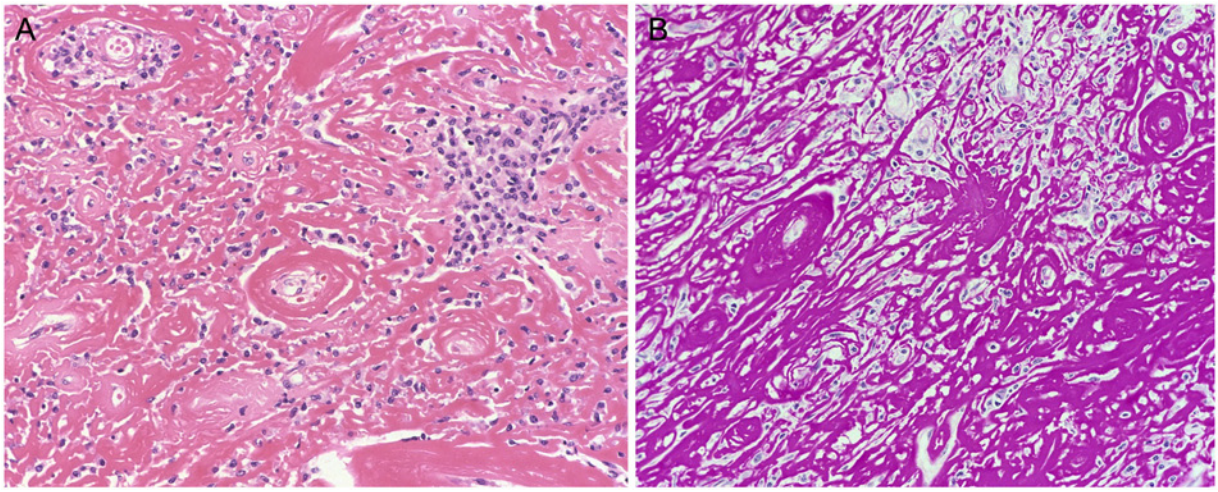

Figure 31. Monoclonal immunoglobulin deposition disease involving soft tissue. (A) The extracellular eosinophilic deposits appear amorphous. (B) The deposits are positive for periodic acid Schiff (PAS).

Table 3. Comparison of Monoclonal Immunoglobulin Deposition Disease With Amyloidosis.

	Monoclonal Immunoglobulin Deposition Disease	Amyloidosis
Histology (H&E stain)	Extracellular amorphous eosinophilic deposits, usually with a homogeneous color	Extracellular amorphous eosinophilic deposits, typically with a blotchy appearance
Special stains	Congo Red − PAS +	Congo Red + PAS −
Immunostaining for amyloid P protein	Negative	Positive
Light chain type	Most commonly kappa	Most commonly lambda
Electron microscopy	Nonfibrillary, often granular and electron-dense	Nonbranching fibrils

Abbreviations: H&E, hematoxylin–eosin; PAS, periodic acid Schiff.

Colors of Extracellular Substances

Extracellular Eosinophilic Deposits

Many different substances can be deposited in the extracellular compartment in the form of pink-staining material, such as collagen (sclerosis), osteoid, amianthoid fibers, skeinoid fibers, Rosenthal fibers, amyloid, immunoglobulin, basement membrane–like material, fibrin, tubular myelin figures (lamellar bodies in lung),[44] and crystals (such as Charcot–Leyden crystals and crystalloids in lumens of neoplastic acini of prostatic carcinoma).

Amyloid is recognized by extracellular eosinophilic materials, typically with a blotchy quality, deposited in irregular patches in the tissue, with predilection for vessel walls. There can be foreign body giant cell reaction, which if present, is more in favor of amyloid over sclerosis. With Congo red stain, amyloid is stained an orange-pink color and exhibits green birefringence. *Monoclonal immunoglobulin deposition disease* is an uncommon complication of plasma cell neoplasm and even less commonly, lymphoma, characterized by nonamyloidotic deposits of immunoglobulins (Figure 31). The immunoglobulins most commonly consist of light chains (also known as light chain deposition disease) but can also consist of heavy chains or even both light and heavy chains.[45-50] Monoclonal immunoglobulin deposition disease and amyloidosis share many similarities, because both represent immunoglobulin deposits in tissue—just that the proteins are aggregated in different ways. The sites of predilection are also similar. The extracellular deposits usually show a homogeneous eosinophilic color, and comparison with amyloid is shown in Table 3.

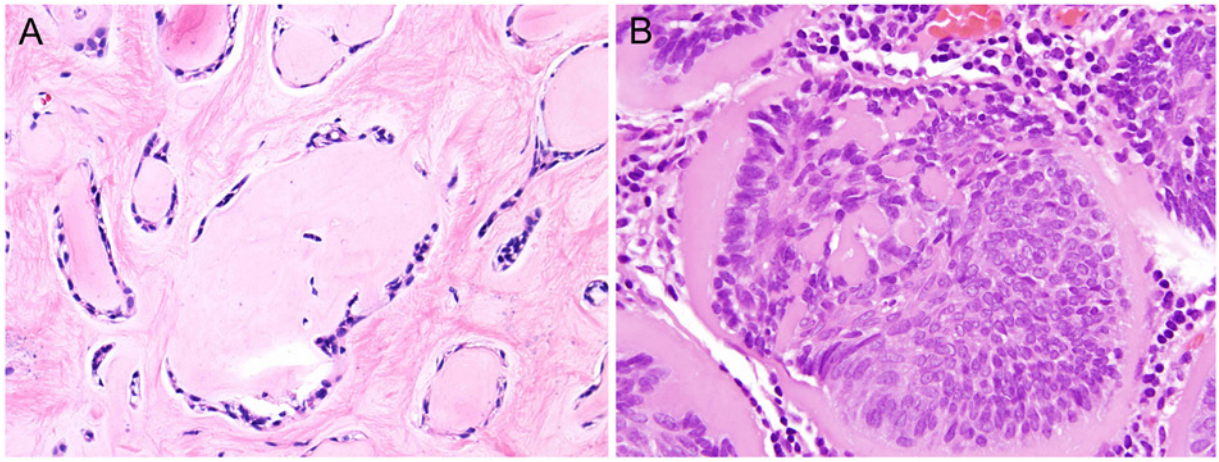

Figure 32. Salivary gland tumors with abundant eosinophilic basement membrane materials. (A) Adenoid cystic carcinoma, with the neoplastic tubules and cribriform structures being "strangulated" by the basement membrane materials. (B) Membranous type of basal cell adenoma, with thick sheaths of basement membrane materials around individual tumor islands. Droplets of the same material are also interspersed throughout the tumor islands.

Abundant basement membrane-like materials can be seen in lesions with a prominent myoepithelial or basal cell component, such as pleomorphic adenoma, epithelial–myoepithelial carcinoma, and cylindroma. The materials can be so abundant that they can "strangulate" and "drown" the tumor cells (Figure 32A). Basement membrane-like materials appear as thick bands and patches with a deep pink color and amorphous quality and are stained by PAS. They may constitute an essential criterion for diagnosis of some entities, such as collagenous spherulosis of the breast and membranous basal cell adenoma of salivary gland (Figure 32B).

Skeinoid fibers are extracellular, brightly eosinophilic, elongated to globular structures with a hyaline quality, formed by collagen. They are of diagnostic value in that they are highly characteristic of gastrointestinal stromal tumors, found almost exclusively in those involving the small bowel or mesentery but not those of other anatomic sites (Figure 33).[51]

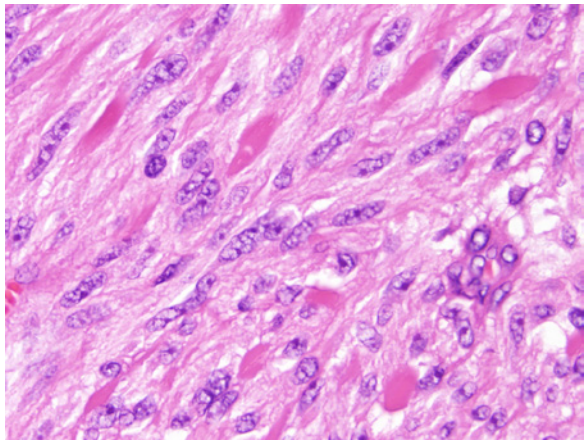

Figure 33. Gastrointestinal stromal tumor of the small intestine. Skeinoid fibers are present among the spindly tumor cells.

Basophilic or Amphophilic Extracellular Deposits

In some disease entities, there is deposition of basophilic or amphophilic materials in the tissue, such as nuclear materials in small cell carcinoma, hematoxylin bodies in systemic lupus erythematosus, mucinous materials, calcification/ossification, and psammoma bodies. They have different mechanisms of formation, resulting in different morphologies (Figure 34).

In small cell carcinomas and some high-grade malignant neoplasms, tumor necrosis is common, resulting in release of nuclear materials (basophilic) that encrust in patches on the walls of blood vessels (Figures 34A and 35). This phenomenon is known as *Azzopardi effect or phenomenon*.[52]

In patients with systemic lupus erythematosus, *hematoxylin bodies* may be found in lymph nodes and sometimes other sites, such as kidney and skin.[53-57] In lymph nodes, hematoxylin bodies are found predominantly in sinusoids but also in the nodal parenchyma or around blood vessels. Hematoxylin bodies are pathognomonic

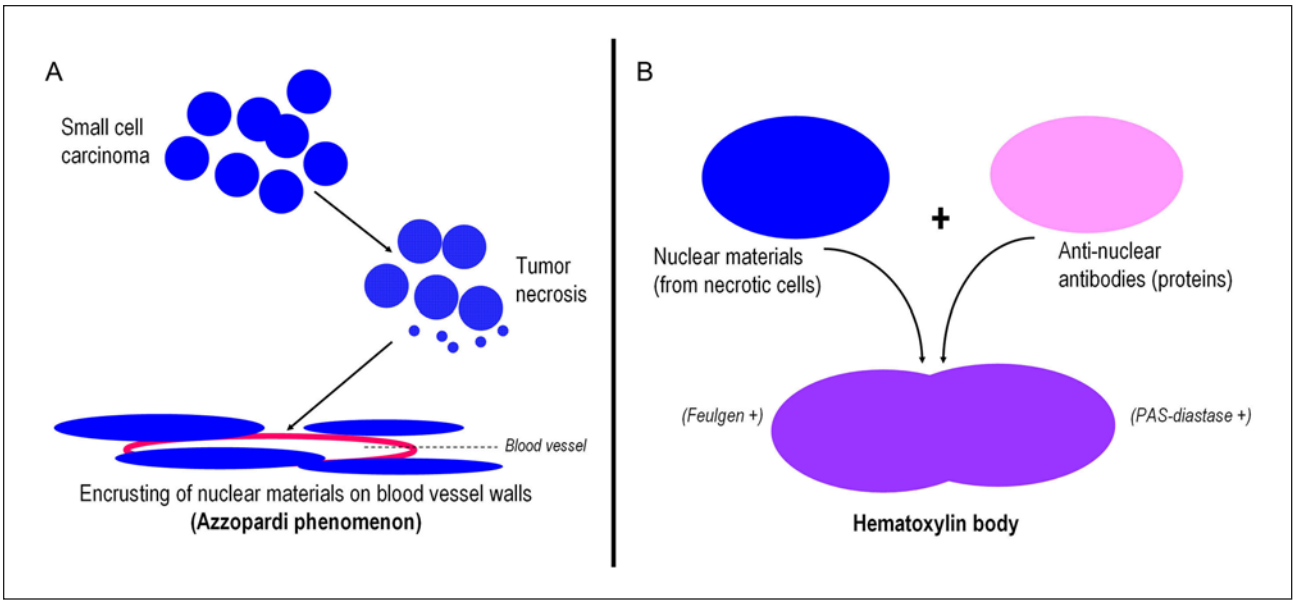

Figure 34. Schematic drawing to show the pathogenesis of extracellular basophilic materials. (A) Azzopardi phenomenon. (B) Hematoxylin body.

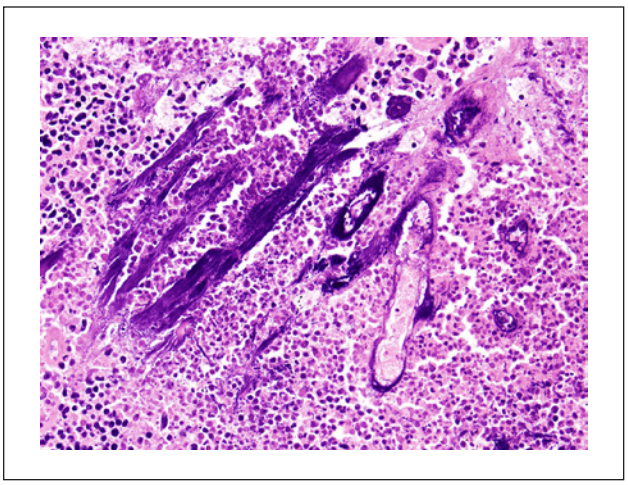

Figure 35. Small cell carcinoma of lung with necrosis and deposition of basophilic nuclear materials on blood vessel walls (Azzopardi phenomenon).

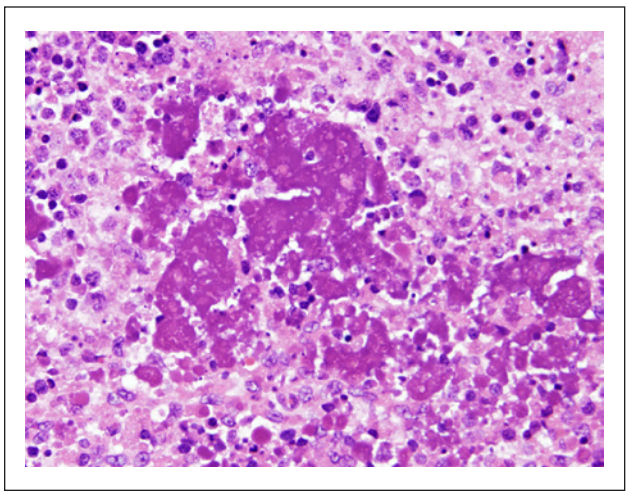

Figure 36. Lupus lymphadenitis, with violaceous hematoxylin bodies.

of systemic lupus erythematosus when present. They are amorphous deposits taking the form of variable-sized patches with characteristic violet color, which differ from the basophilic deposits of Azzopardi phenomenon (Figure 36). This is because the deposits are formed by a combination of denatured nuclear material (basophilic) and antibodies against nuclear materials (eosinophilic; Figure 34B).[55,58]

Acidic mucin gives a light blue color on H&E staining. An exception is Mayer's hematoxylin, which fails to stain acidic mucin. Many different types of soft tissue tumors are characterized by the presence of abundant stromal acidic mucin as a key diagnostic criterion, such as intramuscular myxoma, myxoid liposarcoma, extraskeletal myxoid chondrosarcoma and myxofibrosarcoma. Among carcinomas, the presence of pools of extracellular mucin (epithelium-derived, often lightly basophilic) in which aggregates of carcinoma cells are suspended is the defining feature for mucinous/colloid carcinoma. The presence of blue-tinged (acidic) mucin in the lumens of prostatic

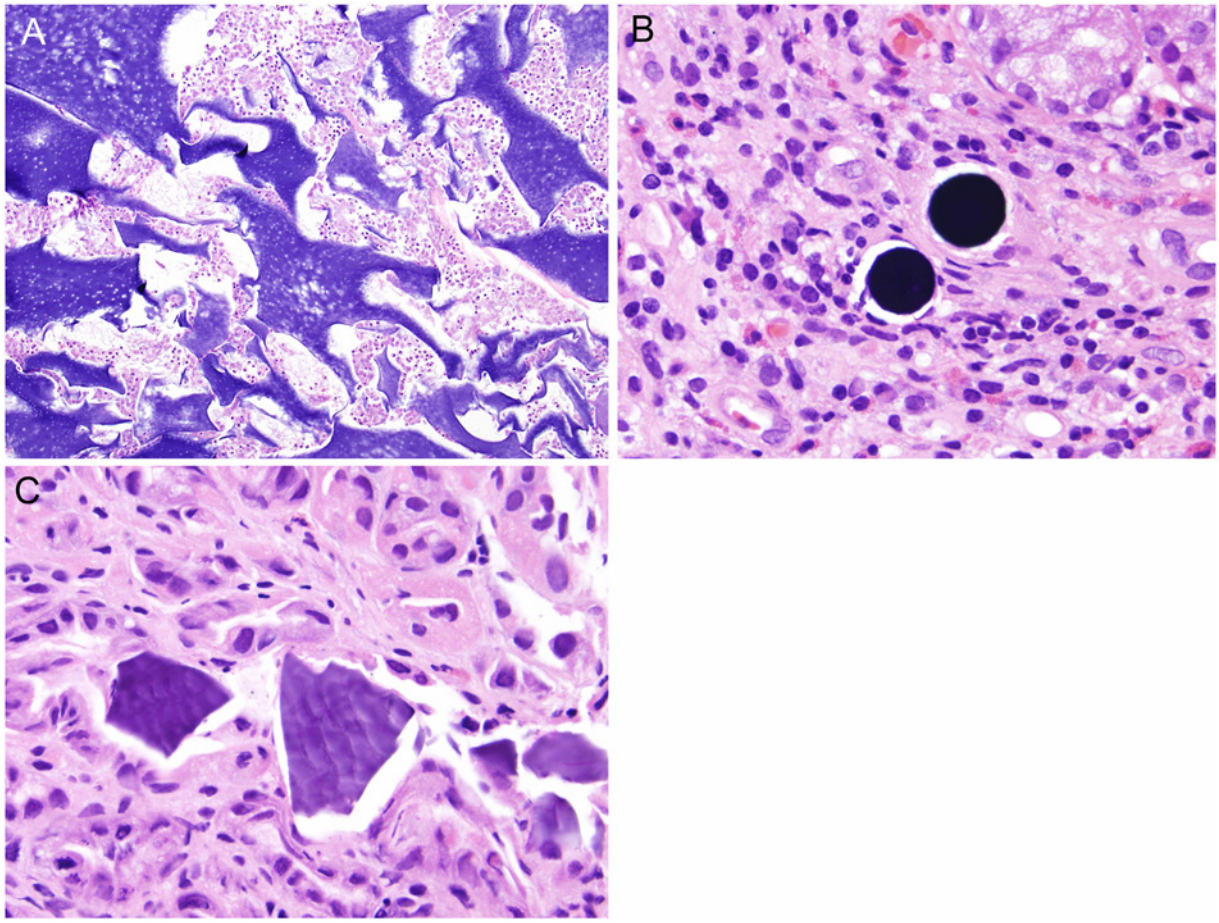

Figure 37. Basophilic foreign materials. (A) Polyacrylamide gel in the breast. This example is accompanied by numerous neutrophils due to superimposed infection. (B) Microspherules of selective internal radiation therapy, in gastric mucosa. (C) Kayexalate in gastric mucosa.

glands is also a clue that would raise a suspicion of carcinoma, because prostatic cells normally contain only neutral mucin (pink).[59]

Psammoma bodies, which are round, laminated, calcified structures, are particularly helpful in diagnosis of certain tumor types because of their frequent presence, such as papillary thyroid carcinoma, hyalinizing trabecular adenoma of thyroid, serous adenocarcinoma of the female genital tract, meningioma, and psammomatous melanotic schwannoma.

Exogenous basophilic materials can sometimes be found in tissues. *Polyacrylamide gel*, which has been used for breast augmentation but banned in many countries, appears as variable-sized, irregular-shaped basophilic to amphophilic material with sharp outlines.[60,61] The material stains homogeneously deep blue or purple, with many interspersed tiny vacuoles, and is nonrefractile and nonbirefringent (Figure 37A). The deeply basophilic and perfectly round microspherules, often surrounded by a narrow retraction space, of *selective internal radiation therapy* are easily recognized as long as one is aware of their existence (Figure 37B).[62] *Kayexalate* (sodium polystyrene sulfonate, also known as resonium), a sodium-containing cation-exchange resin used for treatment of hyperkalemia but which may cause gastrointestinal injury, has a highly characteristic appearance: basophilic plates with a mosaic pattern, resembling fish scales (Figure 37C).[63]

Extracellular Deposits of Other Colors

Hemosiderin and hematoidin deposits, being brown and bright yellow, respectively, represent breakdown products of hemoglobin from red blood cells. They are of no diagnostic significance except to indicate that there has been previous hemorrhage.

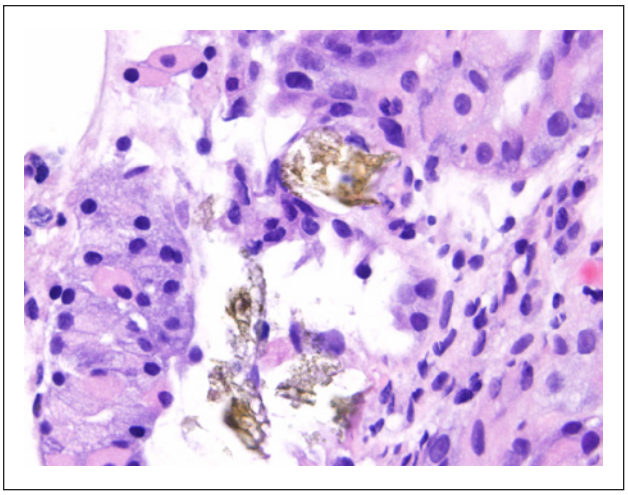

Figure 38. Iron medication impregnated in gastric mucosa.

Iron medication impregnated in the gastric mucosa can be recognized by the refractile, crystalline, golden-brown material deposited in exudate, mucosal surface, and lamina propria, and sometimes in epithelial cells and histiocytes (Figure 38). The importance of its recognition lies in identification of iron medication as a possible etiology of the mucosal injury.

Gamna–Gandy bodies, which represent fibrosiderotic nodules, most commonly occur in the spleen in conditions such as portal hypertension, sickle cell anemia and hemochromatosis.[64] They can also occur in other sites, such as cardiac myxoma or the brain.[65,66] Gamna–Gandy bodies are formed as the end result of hemorrhage, being scars in which collagen and elastic fibers are encrusted with iron and calcium. The encrusted fibers have a greenish, glassy, refractile appearance, and may be segmented or branched, mimicking fungal mycelium.[64] Variable blue staining is present, depending on the amount of calcium deposited.

Conclusions

This review uses examples to illustrate how the simple H&E-stained slide can yield enormous amounts of information about the cells and their functions or aberrations. A prerequisite, of course, is that the histologic section has to be cut well and the H&E stain has to be performed well (with a good balance of colors and contrast), otherwise a lot of diagnostic clues may be lost. For example, if there is inadequate differentiation of the hematoxylin staining, the cytoplasm of the cells and the intercellular stroma may show a strong bluish hue, which will misleadingly make pink-staining structures appear purple-staining.

Declaration of Conflicting Interests

The author declared no potential conflicts of interest with respect to the research, authorship, and/or publication of this article.

Funding

The author received no financial support for the research, authorship, and/or publication of this article.

References

1. King DF, King LA. A brief historical note on staining by hematoxylin and eosin. *Am J Dermatopathol*. 1986;8:168.
2. Avwioro G. Histochemical uses of haematoxylin—a review. *JPCS*. 2011;1:24-34.
3. Fischer AH, Jacobson KA, Rose J, Zeller R. Hematoxylin and eosin staining of tissue and cell sections. *CSH Protoc*. 2008;2008:pdb prot4986.
4. Ip YT, Dias Filho MA, Chan JK. Nuclear inclusions and pseudoinclusions: friends or foes of the surgical pathologist? *Int J Surg Pathol*. 2010;18:465-481.
5. Hayashi I, Tsuda H, Shimoda T. Reappraisal of orthodox histochemistry for the diagnosis of minimal deviation adenocarcinoma of the cervix. *Am J Surg Pathol*. 2000;24:559-562.
6. Cheuk W, Chan JK. Advances in salivary gland pathology. *Histopathology*. 2007;51:1-20.
7. Lack EE. *Tumors of the Adrenal Glands and Extraadrenal Paraganglia. AFIP Atlas of Tumor Pathology, Fourth Series, Fascicle 8*. Washington DC: American Registry of Pathology; 2007:121-122.
8. Tsang WY, Chan JK. KP1 (CD68) staining of granular cell neoplasms: is KP1 a marker for lysosomes rather than the histiocytic lineage? *Histopathology*. 1992;21:84-86.
9. Weiss SW, Goldblum JR. *Enzinger and Weiss's Soft Tissue Tumors*. 5th ed. Philadelphia, PA: Mosby Elsevier; 2008:878-888.
10. Lack EE, Perez-Atayde AR, McGill TJ, Vawter GF. Gingival granular cell tumor of the newborn (congenital "epulis"): ultrastructural observations relating to histogenesis. *Hum Pathol*. 1982;13:686-689.
11. Lazar AJ, Fletcher CD. Primitive nonneural granular cell tumors of skin: clinicopathologic analysis of 13 cases. *Am J Surg Pathol*. 2005;29:927-934.
12. LeBoit PE, Barr RJ, Burall S, Metcalf JS, Yen TS, Wick MR. Primitive polypoid granular-cell tumor and other cutaneous granular-cell neoplasms of apparent nonneural origin. *Am J Surg Pathol*. 1991;15:48-58.
13. Chaudhry IH, Calonje E. Dermal non-neural granular cell tumour (so-called primitive polypoid granular cell tumour): a distinctive entity further delineated in a clinicopathological study of 11 cases. *Histopathology*. 2005;47:179-185.
14. Vyas MC, Sharma R, Malviya A, Kalla AR, Dana R. Granular cell ameloblastoma of jaw. A report of rare case and brief review of literature. *Indian J Cancer*. 1998;35:115-118.

15. Soyer HP, Metze D, Kerl H. Granular cell dermatofibroma. *Am J Dermatopathol*. 1997;19:168-173.
16. Mentzel T, Wadden C, Fletcher CD. Granular cell change in smooth muscle tumours of skin and soft tissue. *Histopathology*. 1994;24:223-231.
17. Lach B, Kanaan I. Granular cell meningioma. A case report. *Folia Neuropathol*. 2007;45:19-22.
18. Kanitakis J, Chouvet B. Granular-cell basal cell carcinoma of the skin. *Eur J Dermatol*. 2005;15:301-303.
19. Giangaspero F, Cenacchi G. Oncocytic and granular cell neoplasms of the central nervous system and pituitary gland. *Semin Diagn Pathol*. 1999;16:91-97.
20. Garcia Prats MD, Lopez Carreira M, Martinez-Gonzalez MA, Ballestin C, Gil R, De Prada I. Granular cell basal cell carcinoma. Light microscopy, immunohistochemical and ultrastructural study. *Virchows Arch A Pathol Anat Histopathol*. 1993;422:173-177.
21. Banerjee SS, Harris M, Eyden BP, Hamid BN. Granular cell variant of dermatofibrosarcoma protuberans. *Histopathology*. 1990;17:375-378.
22. Sobel HJ, Churg J. Granular cells and granular cell lesions. *Arch Pathol*. 1964;77:132-141.
23. Sobel HJ, Marquet E. Granular cells and granular cell lesions. *Pathol Annu*. 1974;9:43-79.
24. Sobel HJ, Avrin E, Marquet E, Schwarz R. Reactive granular cells in sites of trauma. A cytochemical and ultrastructural study. *Am J Clin Pathol*. 1974;61:223-234.
25. Peters E, Gardner DG, Altini M, Crooks J. Granular cell reaction to surgical glove powder. *J Oral Pathol*. 1986;15:454-458.
26. Hicks DG, Judkins AR, Sickel JZ, Rosier RN, Puzas JE, O'Keefe RJ. Granular histiocytosis of pelvic lymph nodes following total hip arthroplasty. The presence of wear debris, cytokine production, and immunologically activated macrophages. *J Bone Joint Surg Am*. 1996;78:482-496.
27. Tamas EF, Epstein JI. Prognostic significance of Paneth cell-like neuroendocrine differentiation in adenocarcinoma of the prostate. *Am J Surg Pathol*. 2006;30:980-985.
28. Kapadia SB, Enzinger FM, Heffner DK, Hyams VJ, Frizzera G. Crystal-storing histiocytosis associated with lymphoplasmacytic neoplasms. Report of three cases mimicking adult rhabdomyoma. *Am J Surg Pathol*. 1993;17:461-467.
29. Dogan S, Barnes L, Cruz-Vetrano WP. Crystal-storing histiocytosis: report of a case, review of the literature (80 cases) and a proposed classification. *Head Neck Pathol*. 2012;6:111-120.
30. Friedman MT, Molho L, Valderrama E, Kahn LB. Crystal-storing histiocytosis associated with a lymphoplasmacytic neoplasm mimicking adult rhabdomyoma: a case report and review of the literature. *Arch Pathol Lab Med*. 1996;120:1133-1136.
31. Kusakabe T, Watanabe K, Mori T, Iida T, Suzuki T. Crystal-storing histiocytosis associated with MALT lymphoma of the ocular adnexa: a case report with review of literature. *Virchows Arch*. 2007;450:103-108.
32. Rossi G, De Rosa N, Cavazza A, et al. Localized pleuropulmonary crystal-storing histiocytosis: 5 cases of a rare histiocytic disorder with variable clinicoradiologic features. *Am J Surg Pathol*. 2013;37:906-912.
33. Lewis JT, Candelora JN, Hogan RB, Briggs FR, Abraham SC. Crystal-storing histiocytosis due to massive accumulation of Charcot-Leyden crystals: a unique association producing colonic polyposis in a 78-year-old woman with eosinophilic colitis. *Am J Surg Pathol*. 2007;31:481-485.
34. Sukpanichnant S, Hargrove NS, Kachintorn U, et al. Clofazimine-induced crystal-storing histiocytosis producing chronic abdominal pain in a leprosy patient. *Am J Surg Pathol*. 2000;24:129-135.
35. Chiosea SI, Griffith C, Assaad A, Seethala RR. The profile of acinic cell carcinoma after recognition of mammary analog secretory carcinoma. *Am J Surg Pathol*. 2012;36:343-350.
36. Skalova A. Mammary analogue secretory carcinoma of salivary gland origin: an update and expanded morphologic and immunohistochemical spectrum of recently described entity. *Head Neck Pathol*. 2013;7(suppl 1):30-36.
37. Cheuk W, Chan JK. Tumors of the salivary gland. In: Fletcher CD, ed. *Diagnostic Histopathology of Tumors*. 4th ed. Philadelphia, PA: Elsevier Saunders; 2013:270-377.
38. Ho KL. Morphogenesis of Michaelis-Gutmann bodies in cerebral malacoplakia. An ultrastructural study. *Arch Pathol Lab Med*. 1989;113:874-879.
39. Zak F. Contribution to the origin, development and experimental production of laminated calcinosiderotic Schaumann bodies. *Acta Med Scand Suppl*. 1964;425:21-24.
40. Jones Williams W. The nature and origin of Schaumann bodies. *J Pathol Bacteriol*. 1960;79:193-201.
41. Azzopardi JG. *Major Problems in Pathology: Volume 11. Problems in Breast Pathology*. London, England: W.B. Saunders; 1979:216-233.
42. Rothenberg HJ, Goellner JR, Carney JA. Hyalinizing trabecular adenoma of the thyroid gland: recognition and characterization of its cytoplasmic yellow body. *Am J Surg Pathol*. 1999;23:118-125.
43. Rothenberg HJ, Goellner JR, Carney JA. Prevalence and incidence of cytoplasmic yellow bodies in thyroid neoplasms. *Arch Pathol Lab Med*. 2003;127:715-717.
44. Beckmann HJ, Dierichs R. Extramembraneous particles and structural variations of tubular myelin figures in rat lung surfactant. *J Ultrastruct Res*. 1984;86:57-66.
45. Preud'homme JL, Aucouturier P, Touchard G, et al. Monoclonal immunoglobulin deposition disease (Randall type). Relationship with structural abnormalities of immunoglobulin chains. *Kidney Int*. 1994;46:965-972.
46. Nasr SH, Valeri AM, Cornell LD, et al. Renal monoclonal immunoglobulin deposition disease: a report of 64 patients from a single institution. *Clin J Am Soc Nephrol*. 2012;7:231-239.
47. Stratta P, Gravellone L, Cena T, et al. Renal outcome and monoclonal immunoglobulin deposition disease in 289 old patients with blood cell dyscrasias: a single center experience. *Crit Rev Oncol Hematol*. 2011;79:31-42.
48. Masai R, Wakui H, Togashi M, et al. Clinicopathological features and prognosis in immunoglobulin light and heavy chain deposition disease. *Clin Nephrol*. 2009;71:9-20.
49. Buxbaum J. Mechanisms of disease: monoclonal immunoglobulin deposition. Amyloidosis, light chain deposition disease, and light and heavy chain deposition disease. *Hematol Oncol Clin North Am*. 1992;6:323-346.

50. Feiner HD. Pathology of dysproteinemia: light chain amyloidosis, non-amyloid immunoglobulin deposition disease, cryoglobulinemia syndromes, and macroglobulinemia of Waldenstrom. *Hum Pathol*. 1988;19:1255-1272.
51. Miettinen M. Gastrointestinal stromal tumor. In: Miettinen M, ed. *Modern Soft Tissue Patholgoy. Tumors and Non-neoplastic Conditions*. New York, NY: Cambridge University Press; 2010:491-507.
52. Azzopardi JG. Oat-cell carcinoma of the bronchus. *J Pathol Bacteriol*. 1959;78:513-519.
53. Grishman E, Churg J. Ultrastructure of hematoxylin bodies in systemic lupus erythematosus. *Arch Pathol Lab Med*. 1979;103:573-576.
54. Wilson RM, Abbott RR, Miller DK. The occurrence of L.E. cells and hematoxylin bodies in the naturally occurring cutaneous lesions of systemic lupus erythematosus. *Am J Med Sci*. 1961;241:31-43.
55. Godman GC, Deitch AD, Klemperer P. The composition of the LE and hematoxylin bodies of systemic lupus erythematosus. *Am J Pathol*. 1958;34:1-23.
56. Medeiros LJ, Kaynor B, Harris NL. Lupus lymphadenitis: report of a case with immunohistologic studies on frozen sections. *Hum Pathol*. 1989;20:295-299.
57. Fox RA, Rosahn PD. The lymph nodes in disseminated lupus erythematosus. *Am J Pathol*. 1943;19:73-99.
58. Bowerfind ES, Jr., Moore RD, Weisberger AS. Histochemical studies of lymph nodes in disseminated lupus erythematosus. *AMA Arch Pathol*. 1956;62:472-478.
59. Epstein JI. Diagnostic criteria of limited adenocarcinoma of the prostate on needle biopsy. *Hum Pathol*. 1995;26:223-229.
60. Leung KM, Yeoh GP, Chan KW. Breast pathology in complications associated with polyacrylamide hydrogel (PAAG) mammoplasty. *Hong Kong Med J*. 2007;13:137-140.
61. Lau PP, Chan AC, Tsui MH. Diagnostic cytological features of polyacrylamide gel injection augmentation mammoplasty. *Pathology*. 2009;41:443-447.
62. Luo DL, Chan JK. Basophilic round bodies in gastritic biopsies little known by pathologists: iatrogenic yttrium 90 microspheres deriving from selective internal radiation therapy. *Int J Surg Pathol*. 2013;21:535-537.
63. Abraham SC, Bhagavan BS, Lee LA, Rashid A, Wu TT. Upper gastrointestinal tract injury in patients receiving kayexalate (sodium polystyrene sulfonate) in sorbitol: clinical, endoscopic, and histopathologic findings. *Am J Surg Pathol*. 2001;25:637-644.
64. Lauder I. The spleen. In: Henry K, Symmers WSC, eds. *Systemic Pathology: Vol. 7. Thymus, Lymph Nodes, Spleen and Lymphatics*. 3rd ed. Edinburgh, Scotland: Churchill Livingstone; 1992:545-609.
65. Kleinschmidt-DeMasters BK. Gamna-Gandy bodies in surgical neuropathology specimens: observations and a historical note. *J Neuropathol Exp Neurol*. 2004;63:106-112.
66. Trotter SE, Shore DF, Olsen EG. Gamna-Gandy nodules in a cardiac myxoma. *Histopathology*. 1990;17:270-272.