Rigshospitalet

REGION

TS-kursus 2021
Pancreas

Overlæge Jane Preuss Hasselby
Patologiafdelingen
Rigshospitalet

Anatomi

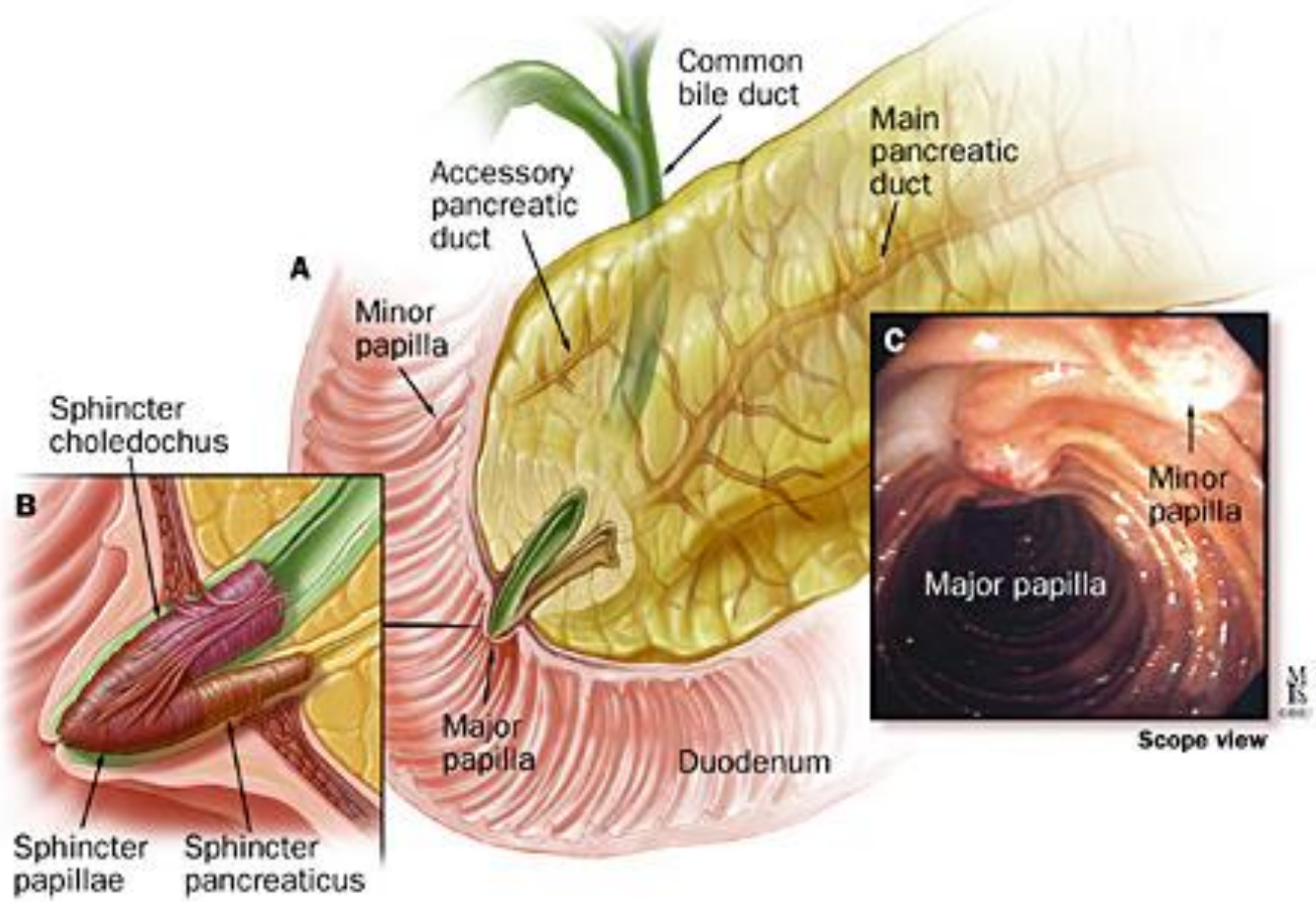
Common bile duct
Main pancreatic duct
Accessory pancreatic duct
A
Minor papilla
Sphincter choledochus
B
C
Minor papilla
Major papilla
Major papilla
Duodenum
Sphincter papillae
Sphincter pancreaticus
Scope view

Rigshospitalet

Histologi

- Opdeles i lobuli af tynde bindevævssepta, fra omkringliggende bindevæv, som indeholder kar, nerver og udførselsgange
- Lobuli består af
  - Eksokrine acini
  - Små intralobulære udførselsgange
  - Langerhanske øer

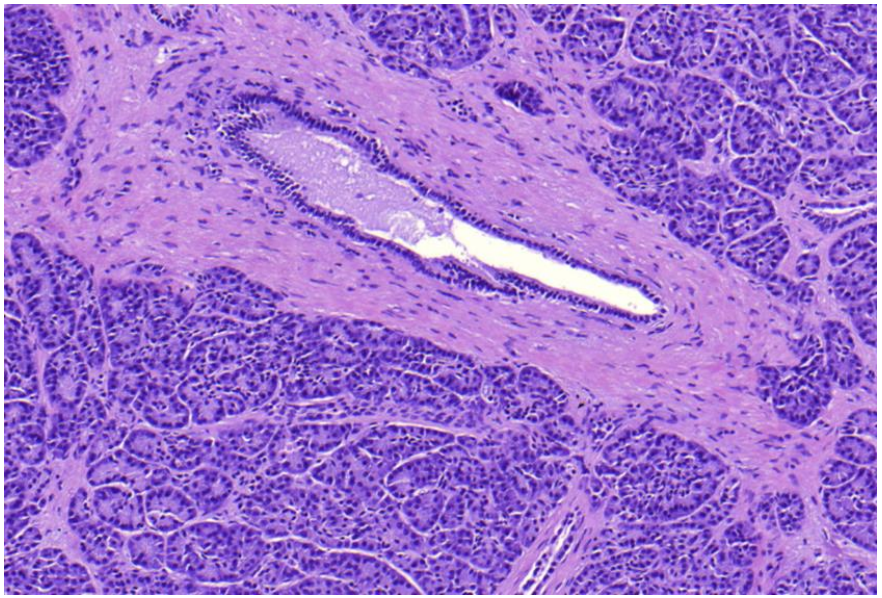

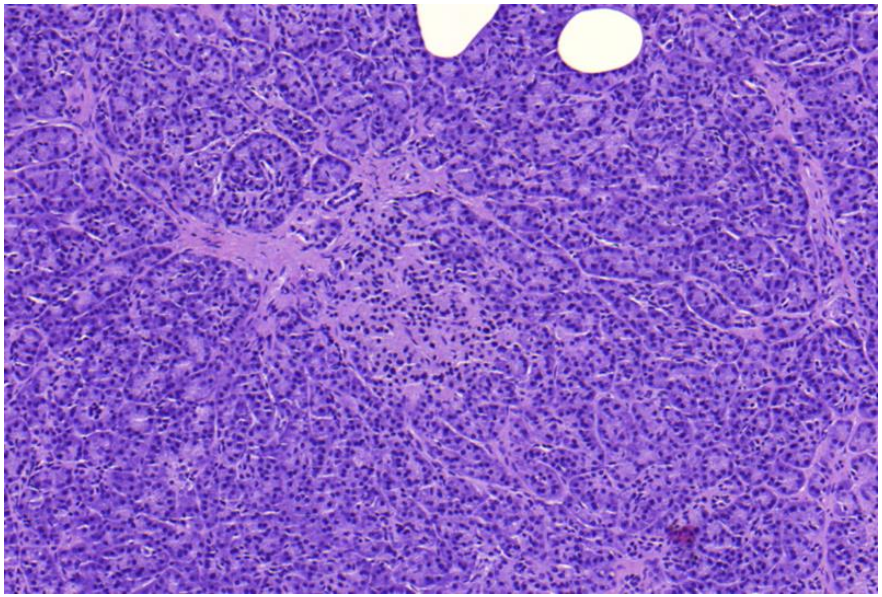

Eksokrine pancreas- histologi

- **Acini**
  - 80% af pancreas
  - Pyramideformede celler, minimalt stroma
  - Basofile celler
  - Veludviklet ru ER
  - Apikalt sekretoriske zymogen granula med fordøjelsesenzymer (PAS+)
- **Centroacinære celler**
  - Findes i centrum af acini, har blegt cytoplasma og oval kerne.
  - Del af udførselsgangsystemet

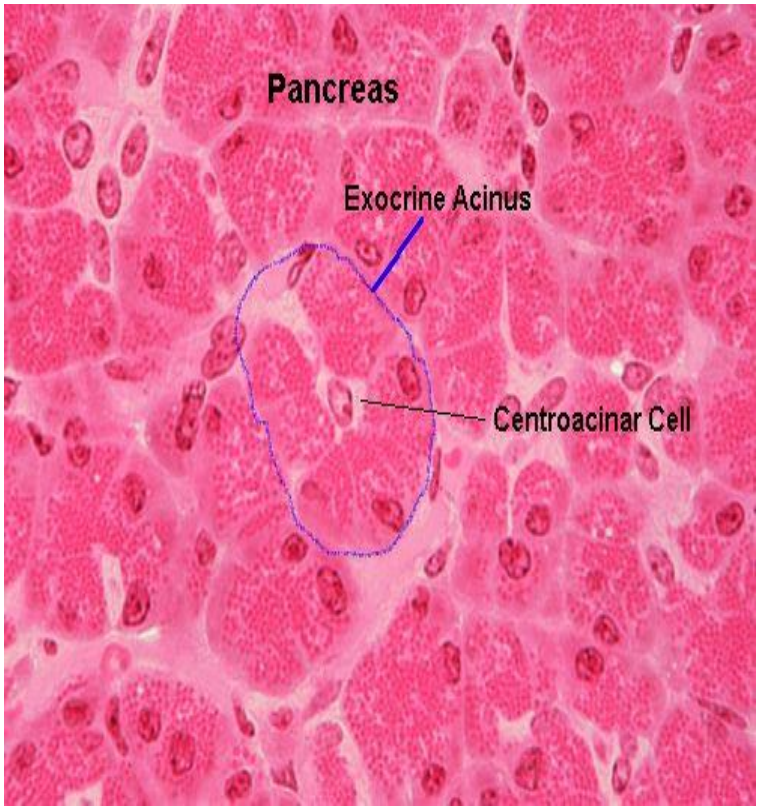

Benigne forandringer

- Cyster
- Akut pancreatitis
- Kronisk pancreatitis

Pancreascyster

- Ægte cyster
  - Kongenitte
    - Polycystisk sygdom
  - Cystisk fibrose
  - Simple mucinøse cyster
  - Mesothelcyster, lymfoepiteliale cyster
  - Non-epitheliale cyster - lymfangiom
- Pseudocyster
- Cystiske tumorer

Pseudocyster

- Lokaliserede ansamlinger af pancreassekret, der opstår efter lækage fra beskadigede gange ud i det interstielle væv
- Udgør ca. 75% af de cystiske læsioner i pancreas
- Udvikles efter
  - Pancreatitis
  - Traumer
  - Sten i ductus
  - Obstruktive neoplasmer

  Symptomer/komplikationer
  - Smerter
  - Blødning
  - Infektion
  - Perforation

  Behandling
  - Drænage (caput)
  - Resektion (corpus/cauda)

Pseudocyster

- Makroskopi
  - 85% solitære
  - Store (3-20 cm)
  - Oftest unilokulære
  - I/nær pancreas
  - Tyk, uregelmæssig væg
  - Flosset indre overflade
  - Skyet indhold
- Mikroskopi
  - Ingen epithelbeklædning
  - Cystevæggen indeholder
    - Histiocytter
    - Kæmpeceller
    - Granulationsvæv
    - Fibrøst væv

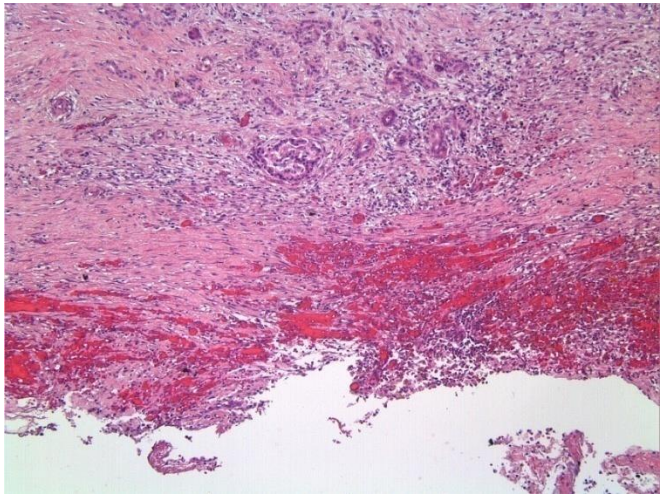

Akut pancreatitis

- Ætiologi og patogenese
  - Ca. 1700 tilfælde/år i DK
  - 2/3 skyldes alkoholisme og galdesten
    - 1/3 – 2/3 af patienterne har galdesten, men kun 5% med galdesten udvikler pancreatitis
    - 75% af galdestensrelaterede tilfælde ses hos kvinder
    - 85% af alkoholrelaterede tilfælde ses hos mænd
  - Mekanismer
    - Obstruktion af fælles gang mellem ductus choledochus og ductus pancreaticus major → overløb af galde til pancreasgang → epithelbeskadigelse og enzymaktivering
    - Galderefluks
    - Spasmer i sphincter Oddi
    - Obstruktion af små gange → trykforhøjelse og ruptur
    - Mekanismen bag den intrapancreatiske enzymaktivering ved alkoholisk pancreatitis er uafklaret
  - Fysiologi
    - Skyldes autodigestion pga. uhensigtsmæssig aktivering af fordøjelsesenzymer

Akut pancreatitis ætiologi

Alkohol

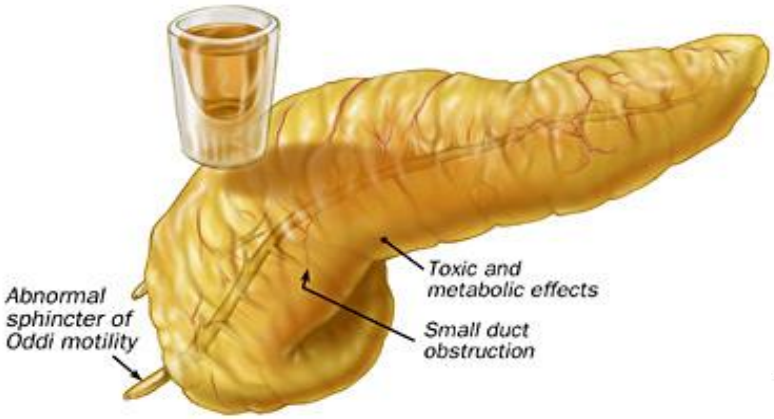

Lithiasis

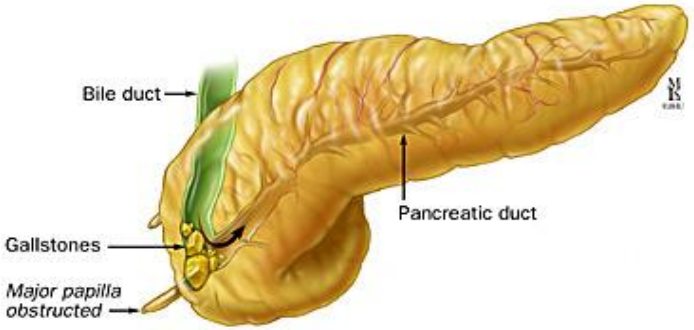

Mikrolithiasis?

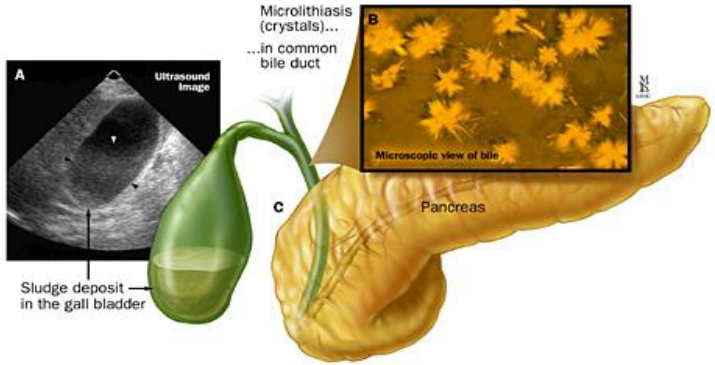

Akut pancreatitis

- Makroskopi
  - Lette tilfælde (90%)
    - Ødem
    - Bevaret mikrovaskulatur
  - Svære – fulminante tilfælde
    - Blødning
    - Nekrose
    - Fedtnekroser (stearinpletter)
    - Cystisk henfald

Akut pancreatitis

- Mikroskopi
  - Ødem
  - Inflammation
  - Nekrose
  - Blødning
  - Kalcifikation (udfældning af calciumsalte af fede syrer)

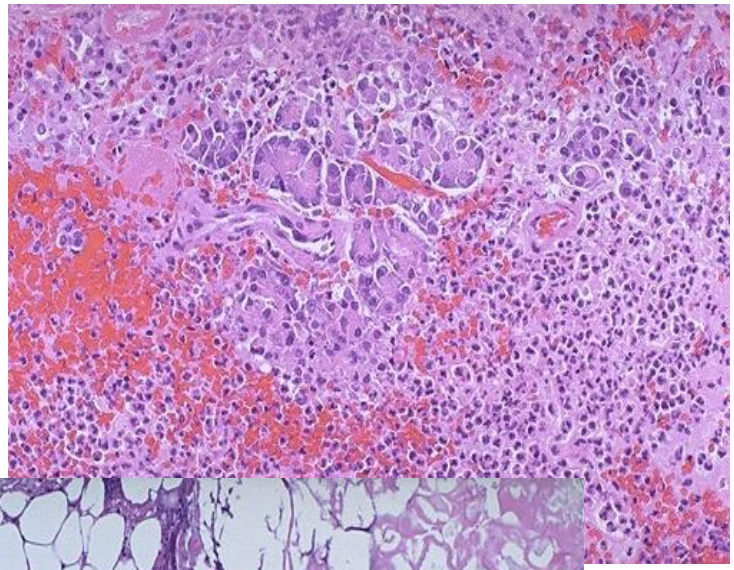

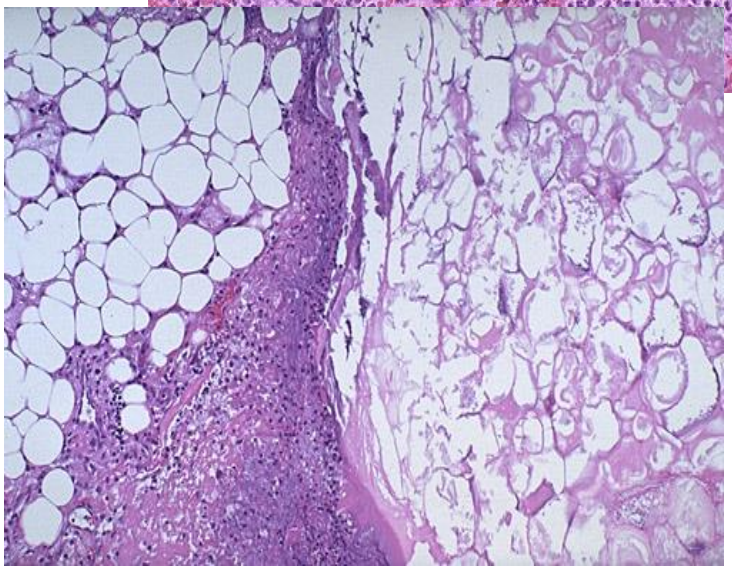

Kronisk pancreatitis

- Definition
  - Kronisk fibroserende inflammation med atrofi af især det eksokrine væv
  - Pancreasinsufficiens
  - Ca. 500 tilfælde/år i DK
- Ætiologi
  - Kronisk kalcificerende (95%)
    - **Kronisk alkoholisme**
    - Metaboliske sygdomme
    - Hereditær, autosomal dom., 80% penetrans
  - Kronisk obstruktiv
    - Galdevejslidelser
    - Tumorer (pancreas og papilla Vateri)
    - Pancreas divisum
  - Groove pancreatitis- paraduodenal pancreatitis
  - Autoimmun

Kronisk pancreatitis stadier

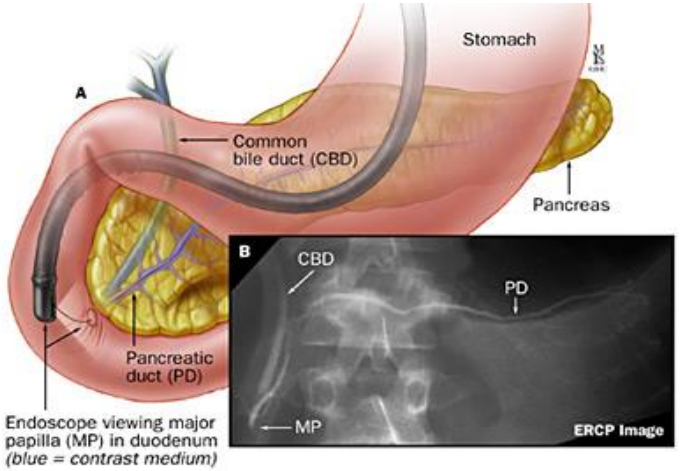

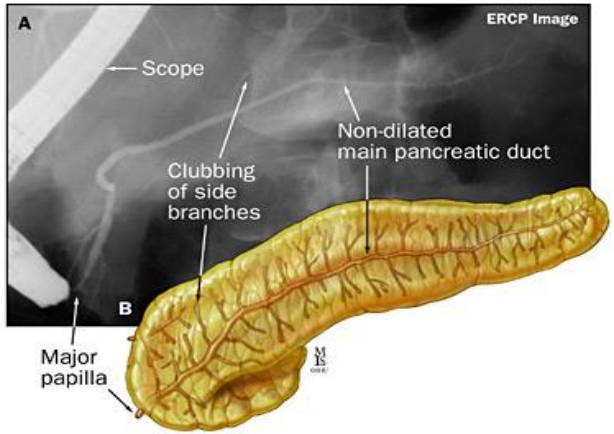

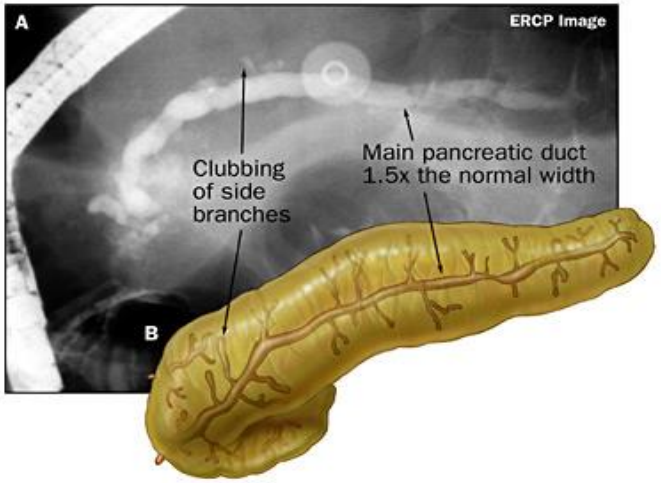

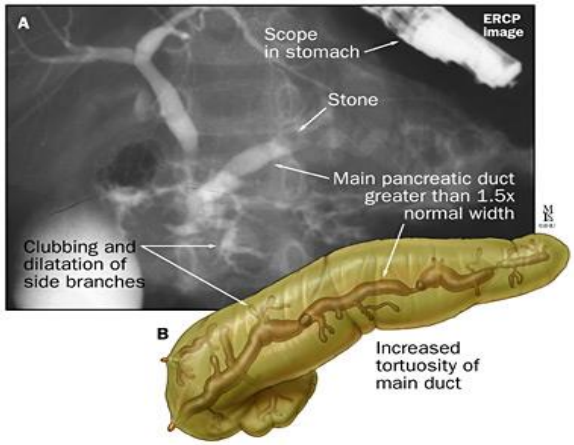

Kronisk kalcificerende pancreatitis

- Makroskopi
  - Hårdt og fibrøst parenkym
  - Ductus pancreaticus major slynget og med varierende kaliber
  - Dilaterede gange
  - Synlige konkrementer
  - Pseudocyster

Kronisk kalcificerende pancreatitis

- Mikroskopi
  - Tab af acini med relativt velbevarede Langerhanske øer
  - Fibrose – intra og interlobulært
  - Kronisk inflammation
  - Dilaterede gange indeholdende proteinplugs
  - Gangepithel
    - Atrofisk
    - Hyperplastisk
    - Pladeepitelmetaplasi

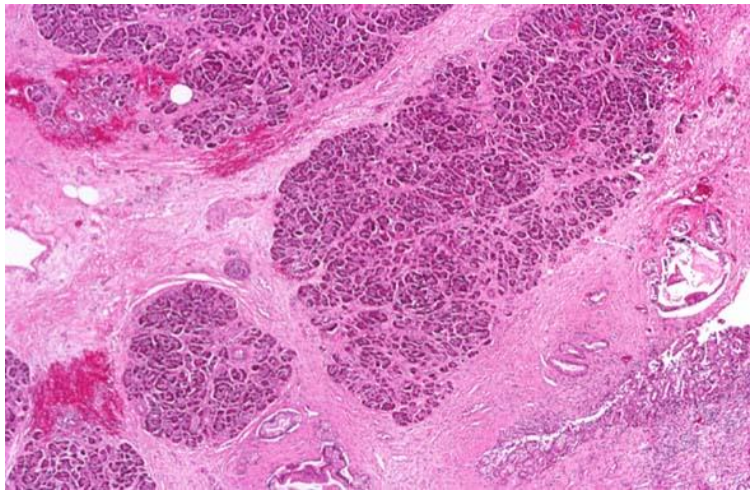

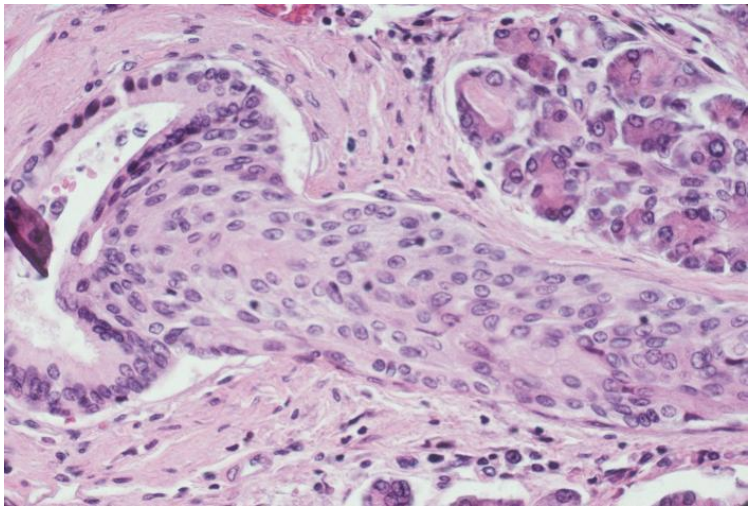

Rigshospitalet

Dilaterede og proteinplugs
Ø-vævs hyperplasi

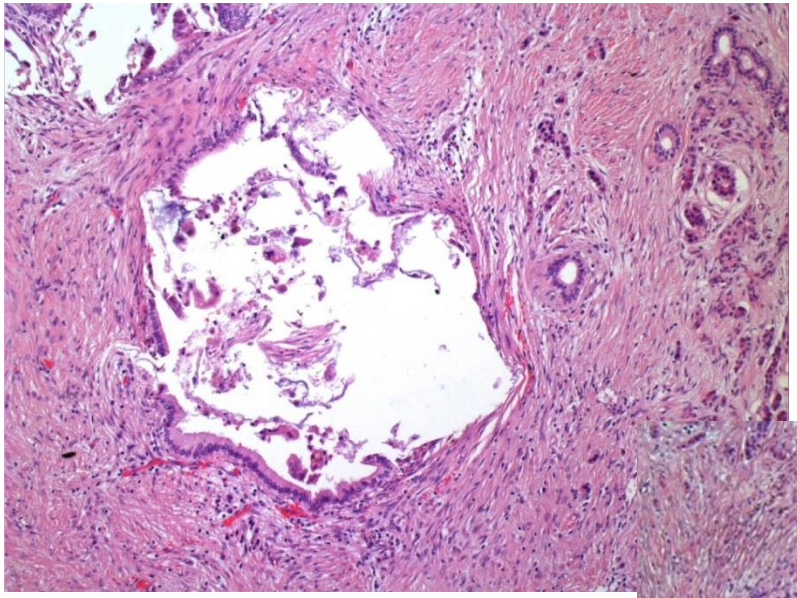

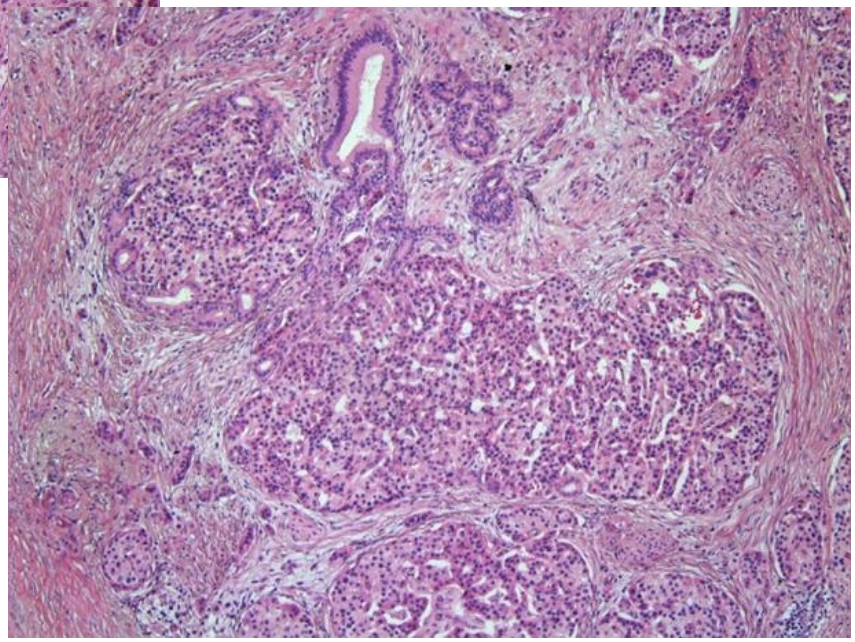

Groove pancreatitis
- paraduodenal pancreatitis

- Kronisk inflammation i området mellem duodenum, pancreas og choledochus
- Hyppigt relateret til alkohol
- Abnormiteter ved papilla minor?
- Mistolkes ofte som en malign proces
- Svære abdominalsmerter, ikterus, madlede, kvalme, opkastning, vægttab

Groove pancreatitis

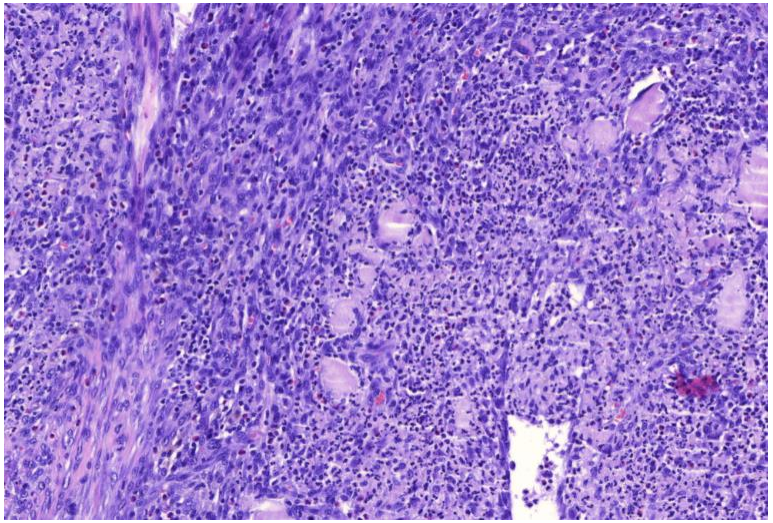

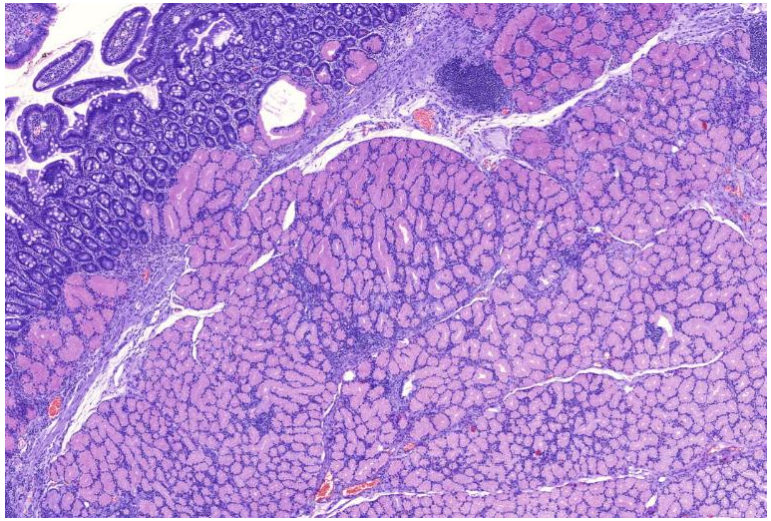

- Ektopisk pancreasvæv og pseudocyster i duodenalvæggen
- Granulationsvæv og fremmedlegeme kæmpeceller
- Hyperplasi af Brunner kirtlerne

Rigshospitalet

Groove pancreatitis

- Udtalt myofibroblastær og neural proliferation
- Fibrose i det tilgrænsende pancreasvæv

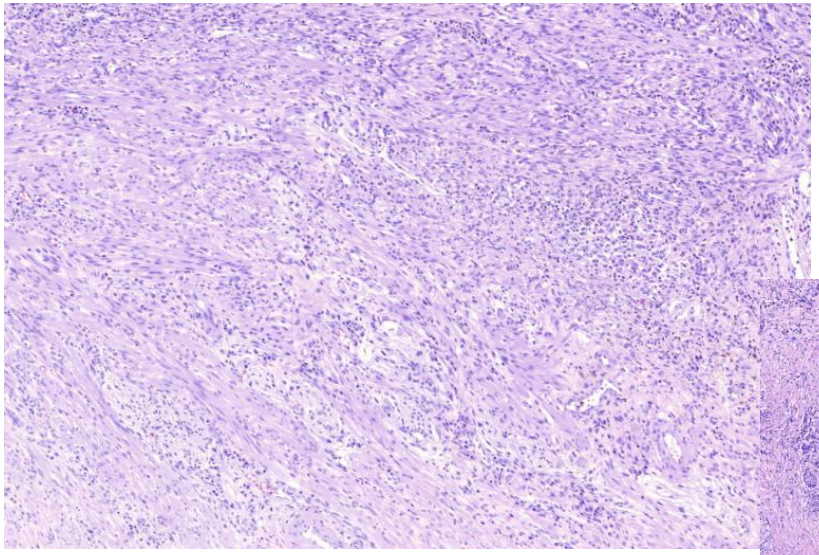

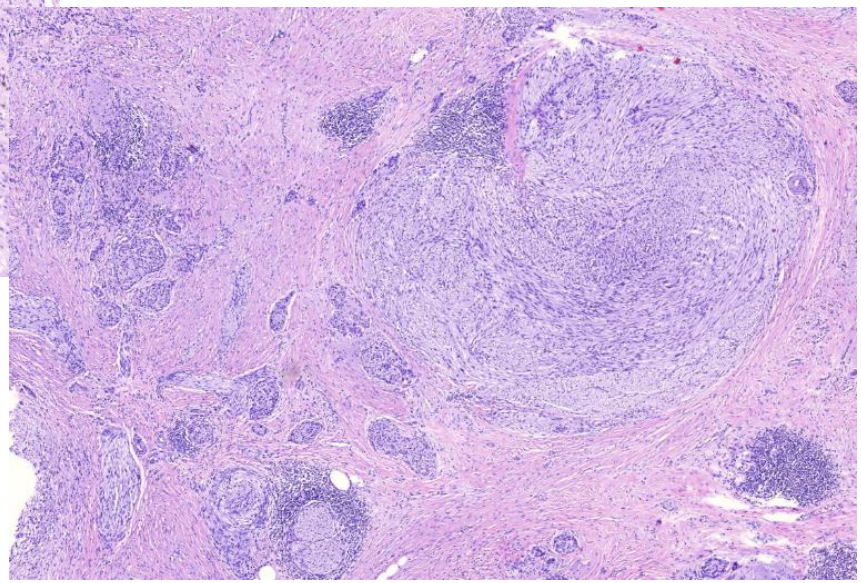

Autoimmun pancreatitis

- Kronisk inflammation og fibrose
- Let abdominalia, ikterus
- To subtyper
  - IgG4 relateret subtype, type 1
    - Ofte ældre mænd
    - Symptomer på ekstrapancreatisk sygdom
    - IgG og evt. IgG4 forhøjet i serum
    - Autoantistoffer
  - Ikke-IgG4 relateret subtype, type 2
    - <40 år, F=M
    - Associeret til IBD, ca. 30%
- Ofte operation på mistanke om cancer

Rigshospitalet

Type 1

- Lymfoplasmacytær skleroserende pancreatitis (LPSP)
- Ratio IgG4/IgG >40
- > 10 IgG4 pos. plasmaceller per HPF
- Steroid/ Rituximab

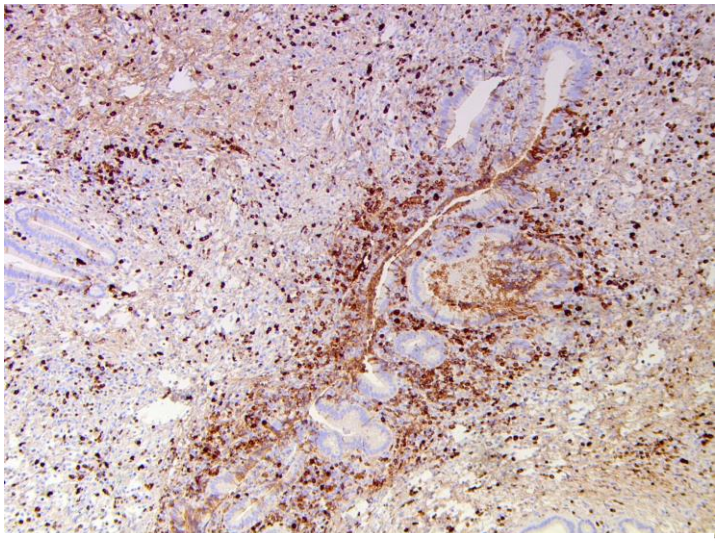

Mange IgG4 positive plasmaceller

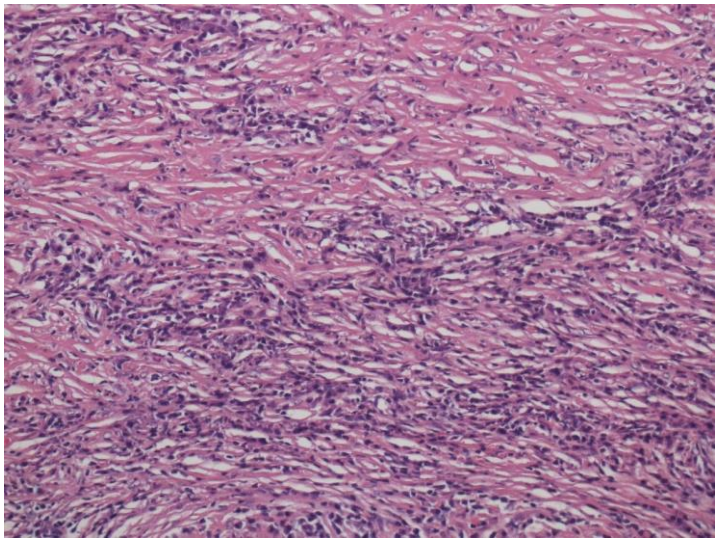

Storiform fibrose

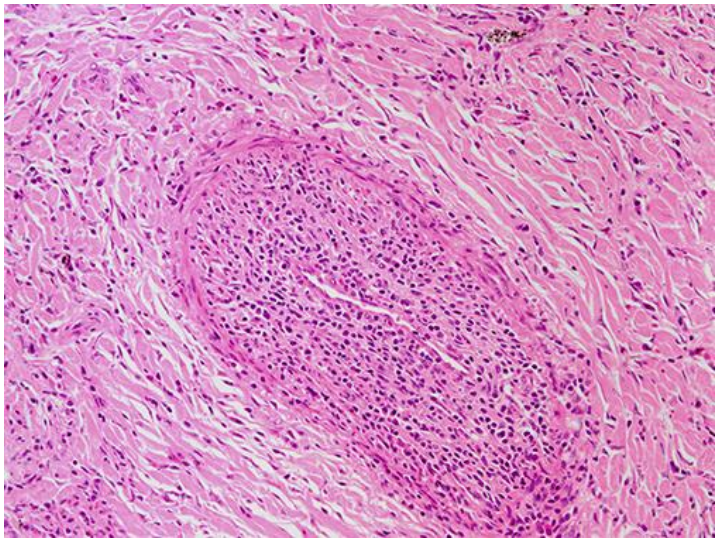

Obliterative flebitis

Rigshospitalet

Type 2

- Idiopatisk ductcentrisk pancreatitis (IDCP)
- Granulocytic epithelial lesions (GEL)

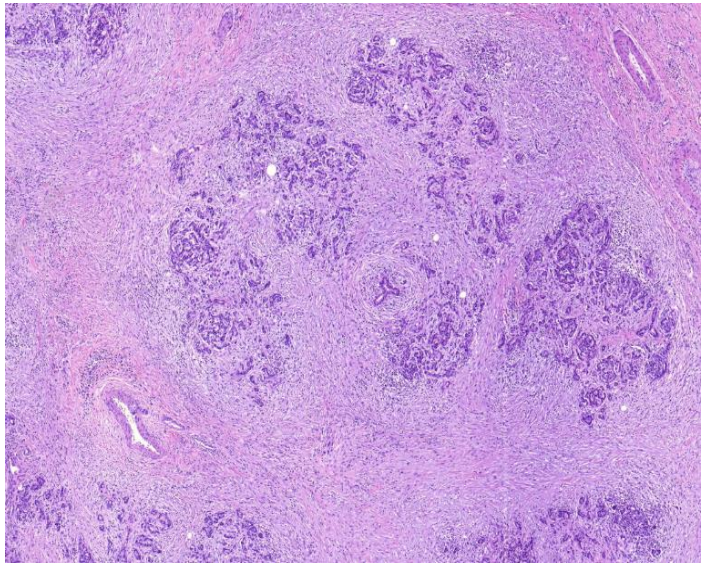

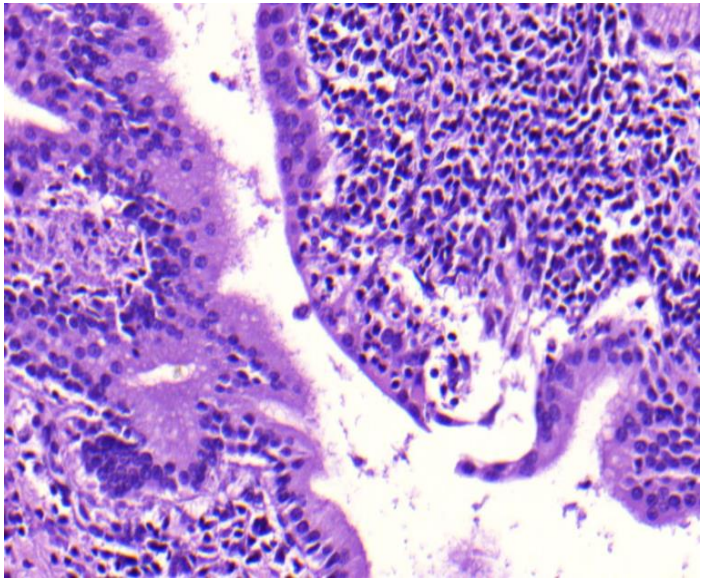

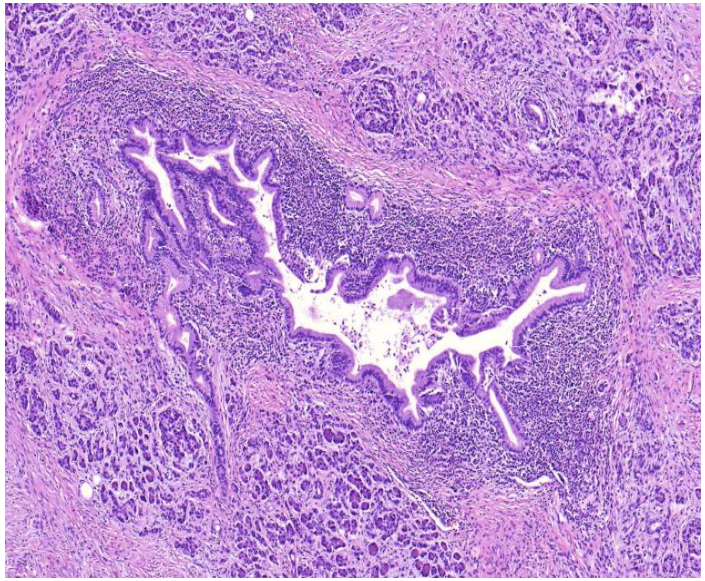

Neoplasier i pancreas

Duktalt adenokarcinom

- Udgør 85% af samtlige maligne tumorer i pancreas
- Ca. 970 tilfælde/år i DK, ingen kønsforskel
- Risikofaktorer
  - Sporadiske
    - Cigaretrygning (fordobling af risiko)
    - Alkoholmisbrug
    - Fedme
    - DM
    - Kronisk pancreatitis
  - Familiære tilfælde (<10%)
    - Cystisk fibrose
    - Hereditær pancreatitis
    - HNPCC
    - Familiær brystkræft med BRCA mutation

Diagnostik

Præoperativ diagnostik

- Ultralyd – tumor størrelse, lokalisation, evt metastaser
- CT-scanning - tumor størrelse og lokalisation
- MR-scanning - tumor størrelse og lokalisation
- Ultralyds/CT-vejledt perkuntan FNA/histologisk biopsi- diagnose
- Endoskopisk Retrograd Cholangiografi (ERCP) – displacering, forsnævring eller obstruktion af ductus pancreaticus,evt. cytologi
- Endoskopisk Ultralyd (EUS) – tumor størrelse og lokalisation, lymfeknuder – præoperativ staging

Peroperativ diagnostik

- FNA
- Grovnål (frysesnit)

Cytologi

- Børstebiopsier
- FNA

Tumoraspirater

- Cellulære, oftest uden acinære celler eller ø-celler.
- Atypiske duktale celler i flager, grupper eller enkeltliggende
- Forstørrede kerner, mitoser
- Eventuel forekomst af benigne duktale celler

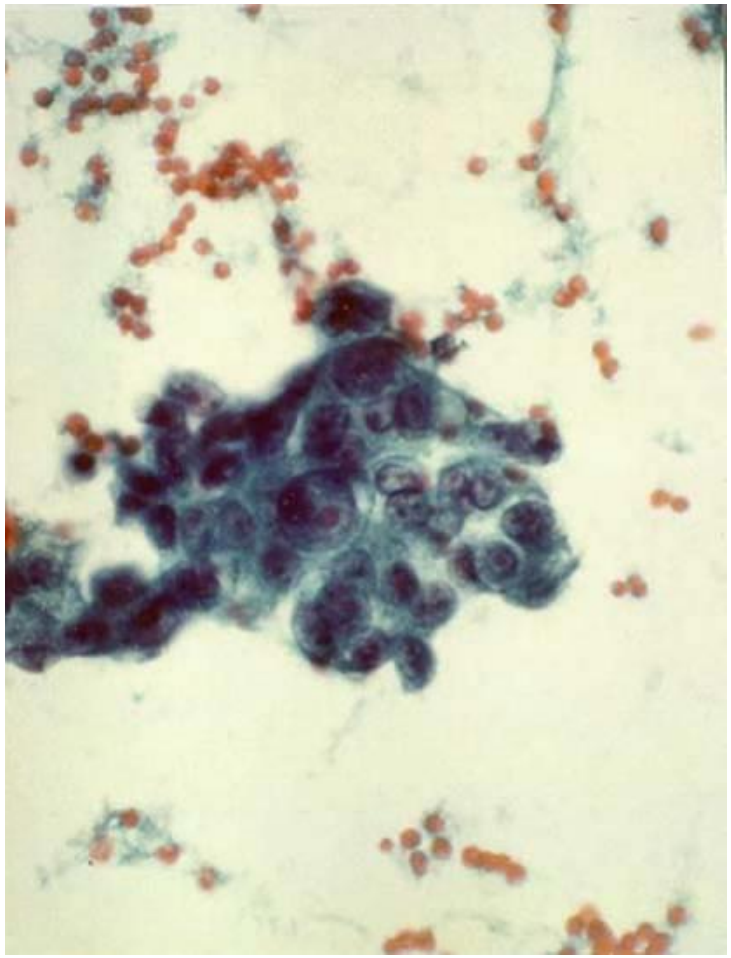

66-årig kvinde med en relativt velafgrænset, hypoekkoisk proces i caput pancreatis samt dilatation af ductus pancreaticus.

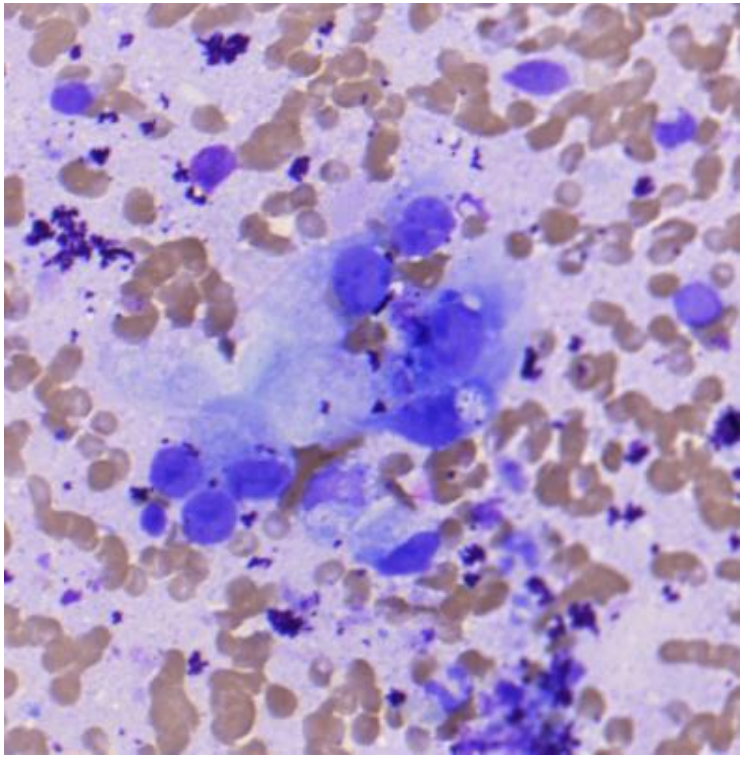

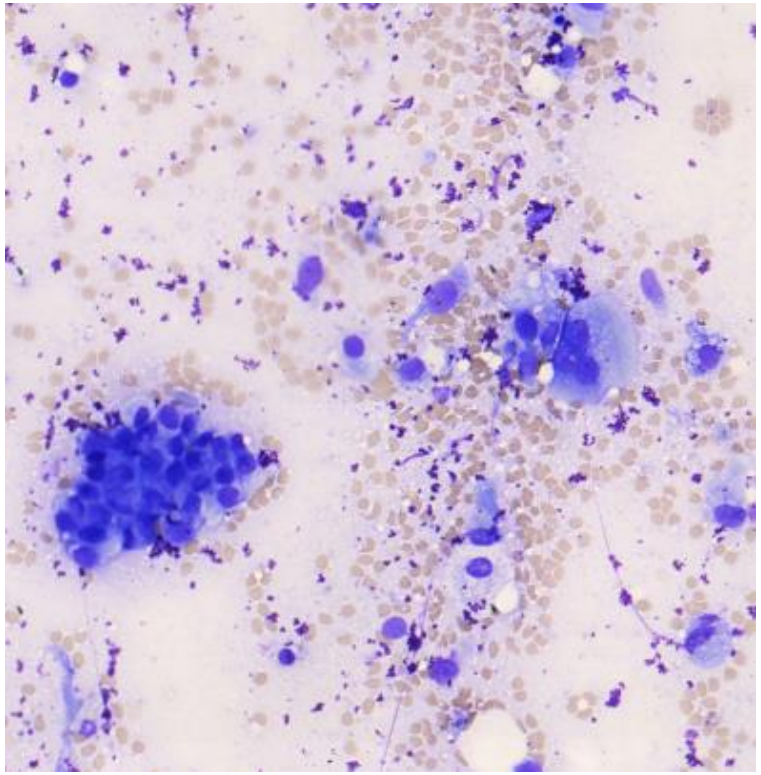

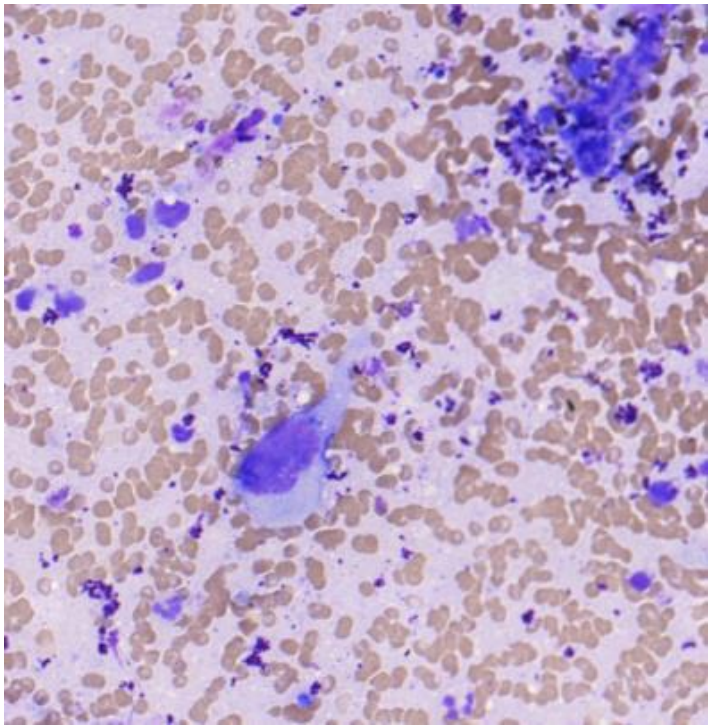

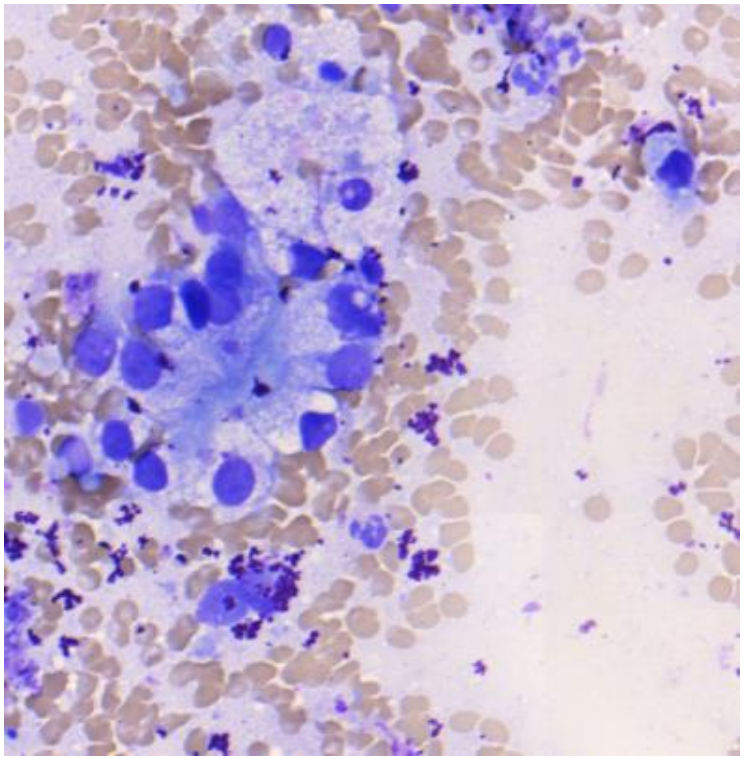

Kronisk pancreatitis versus adenokarcinom

- Pt.'s alder
  - AC meget sjælden før 40 års alderen
- Morfologi ved lav forstørrelse
  - Bevarelse af lobulær opbygning?
- Morfologi ved høj forstørrelse
  - Kernemorfologi?
  - Rumperede duktale strukturer?
- IHC
  - Positiv reaktion for mCEA og MUC1 taler for AC
  - Positiv reaktion for p53 og høj proliferationsrate bedømt på Ki67 taler for AC
  - Tab af SMAD4 taler for AC

Kronisk pancreatitis versus adenokarcinom

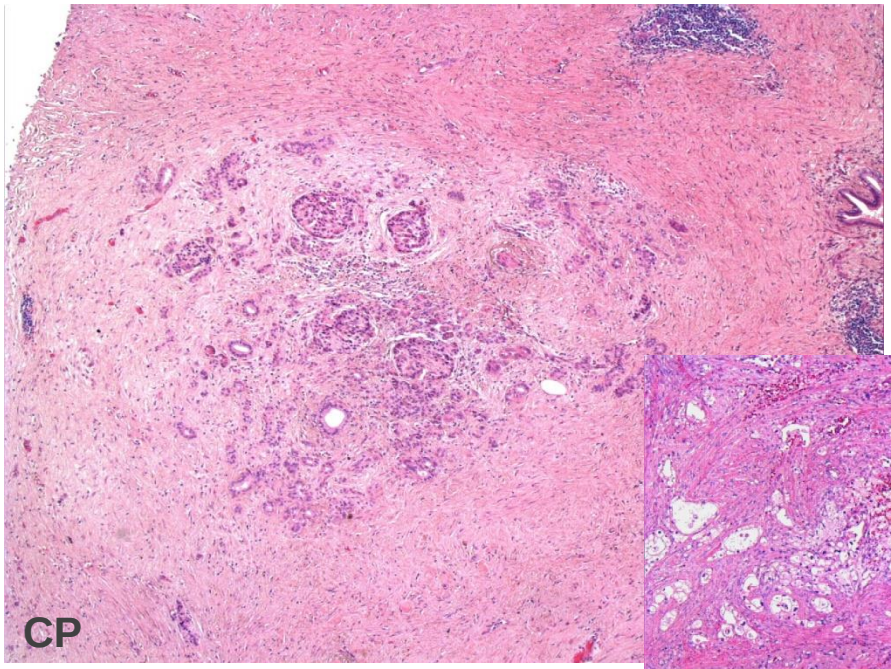

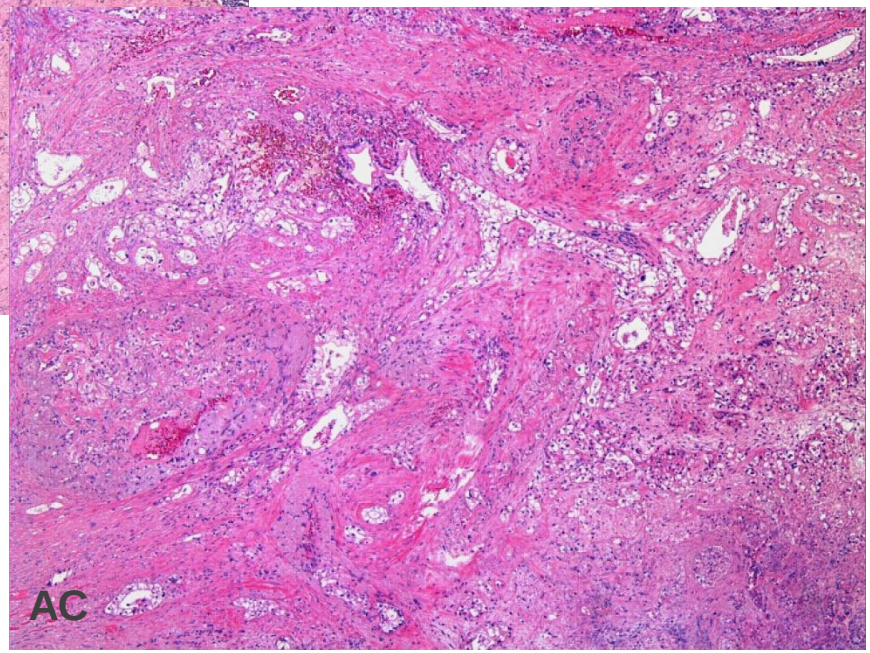

Kronisk pancreatitis versus adenokarcinom

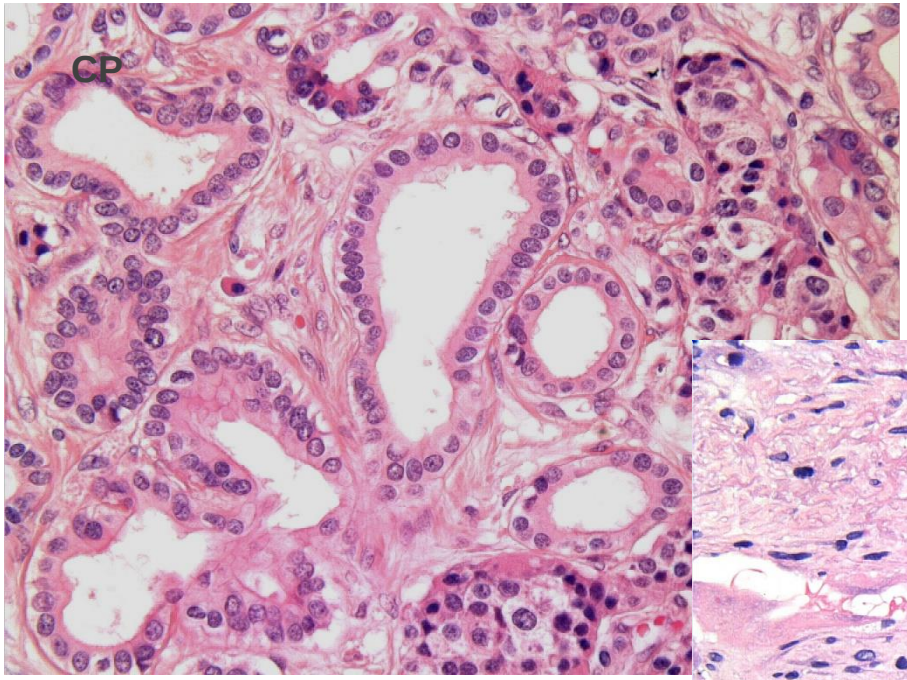

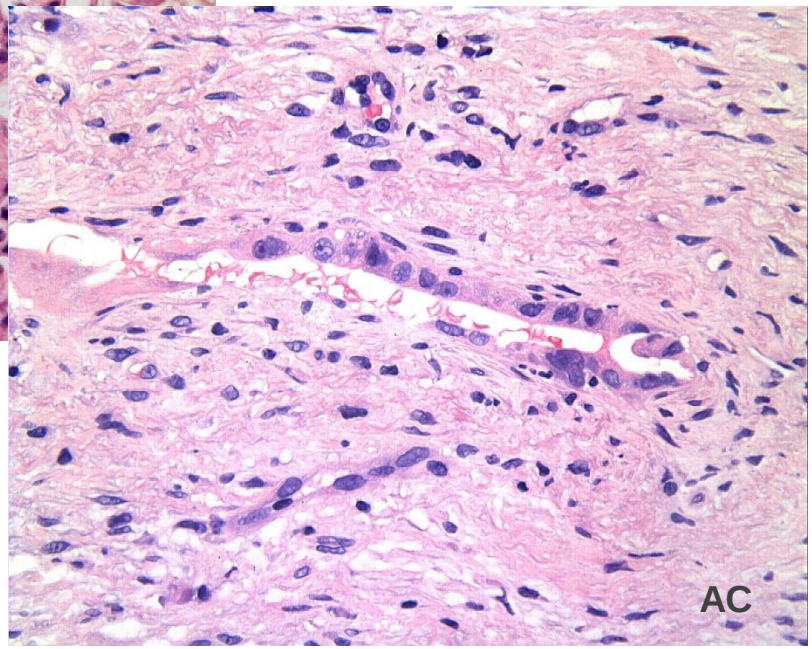

Whipples operation

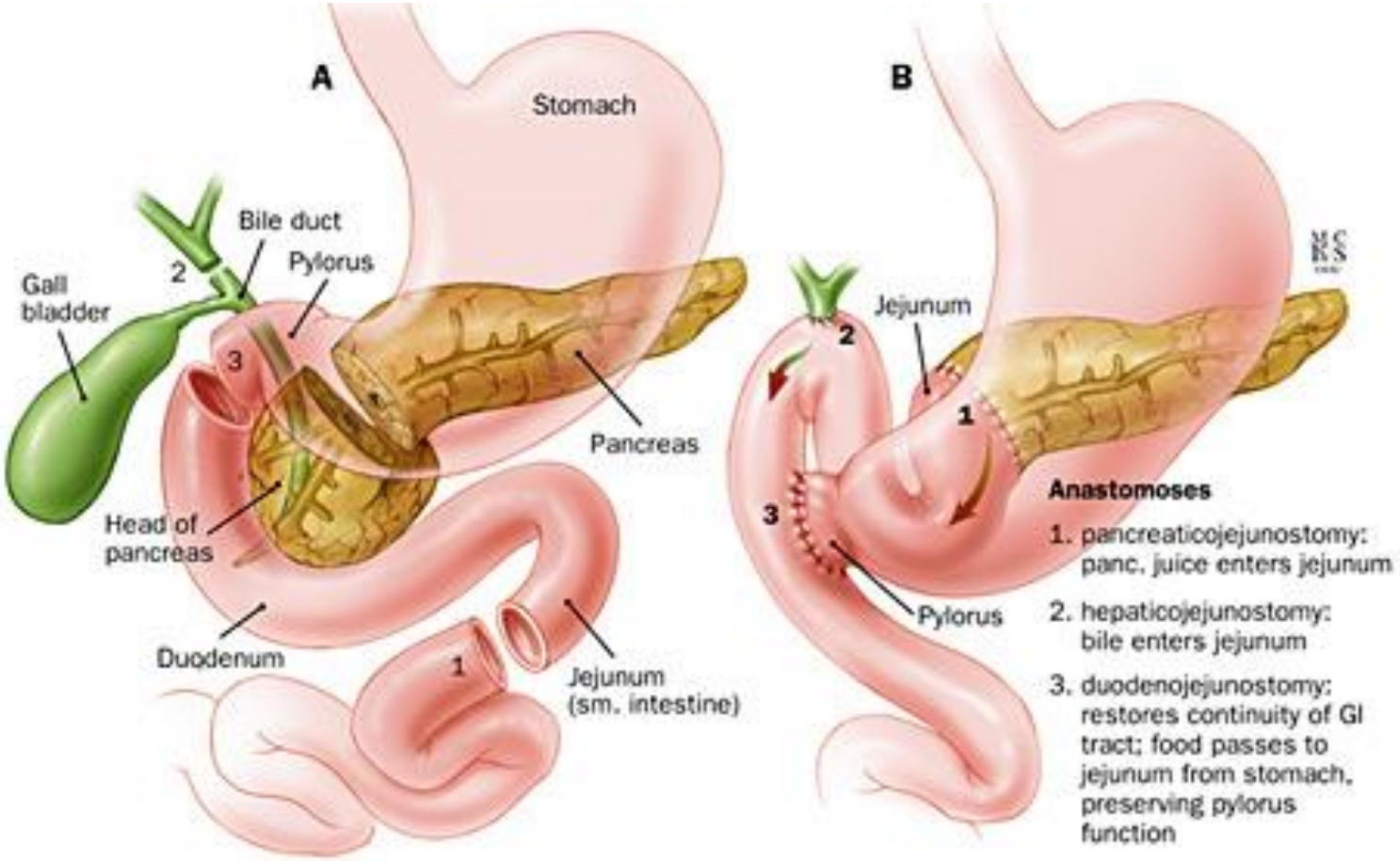

Whipple operationspræparat

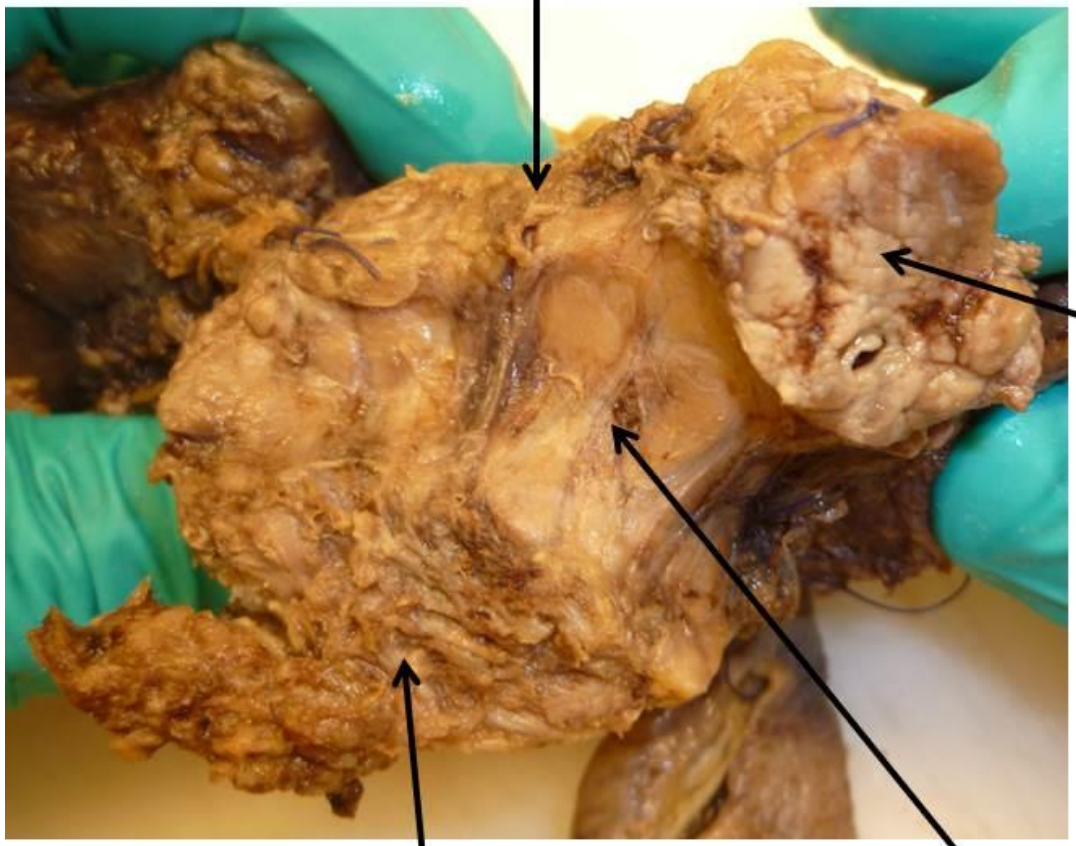
Anteriore flade
(tusches grøn)
Laterale
resektionsrand
VMS resektionsranden
(tusches blå)
AMS resektionsranden
(tusches rød)

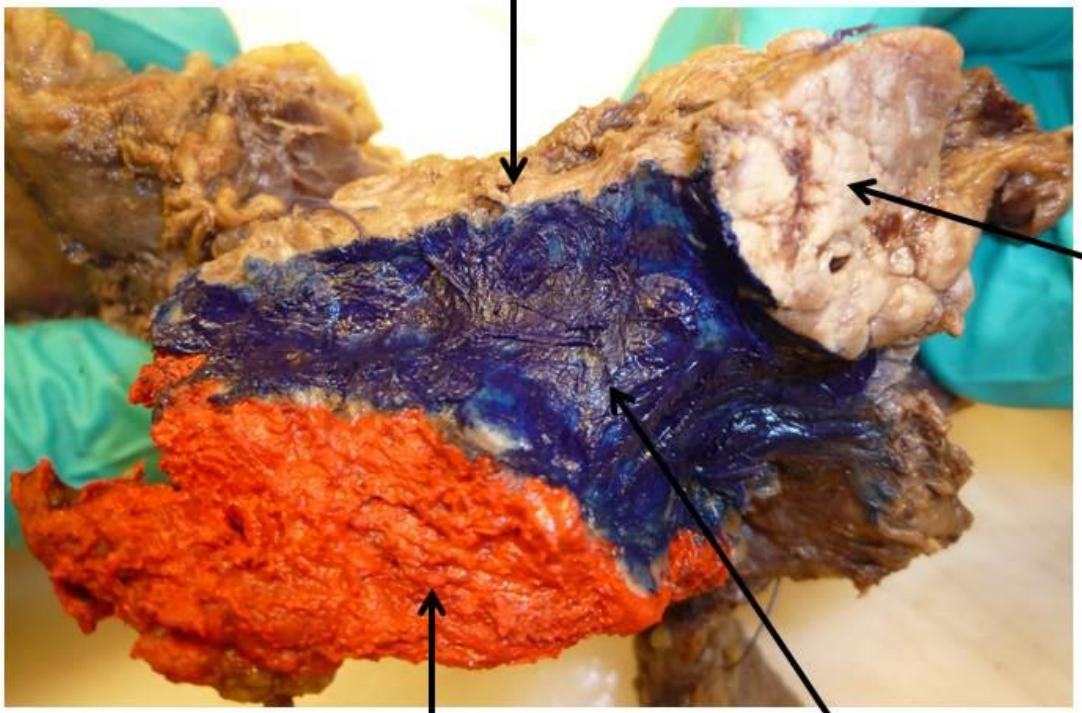
Anteriore flade
(tusches grøn)
Laterale
resektionsrand
AMS resektionsranden
(tusches rød)
VMS resektionsranden
(tusches blå)

Rig

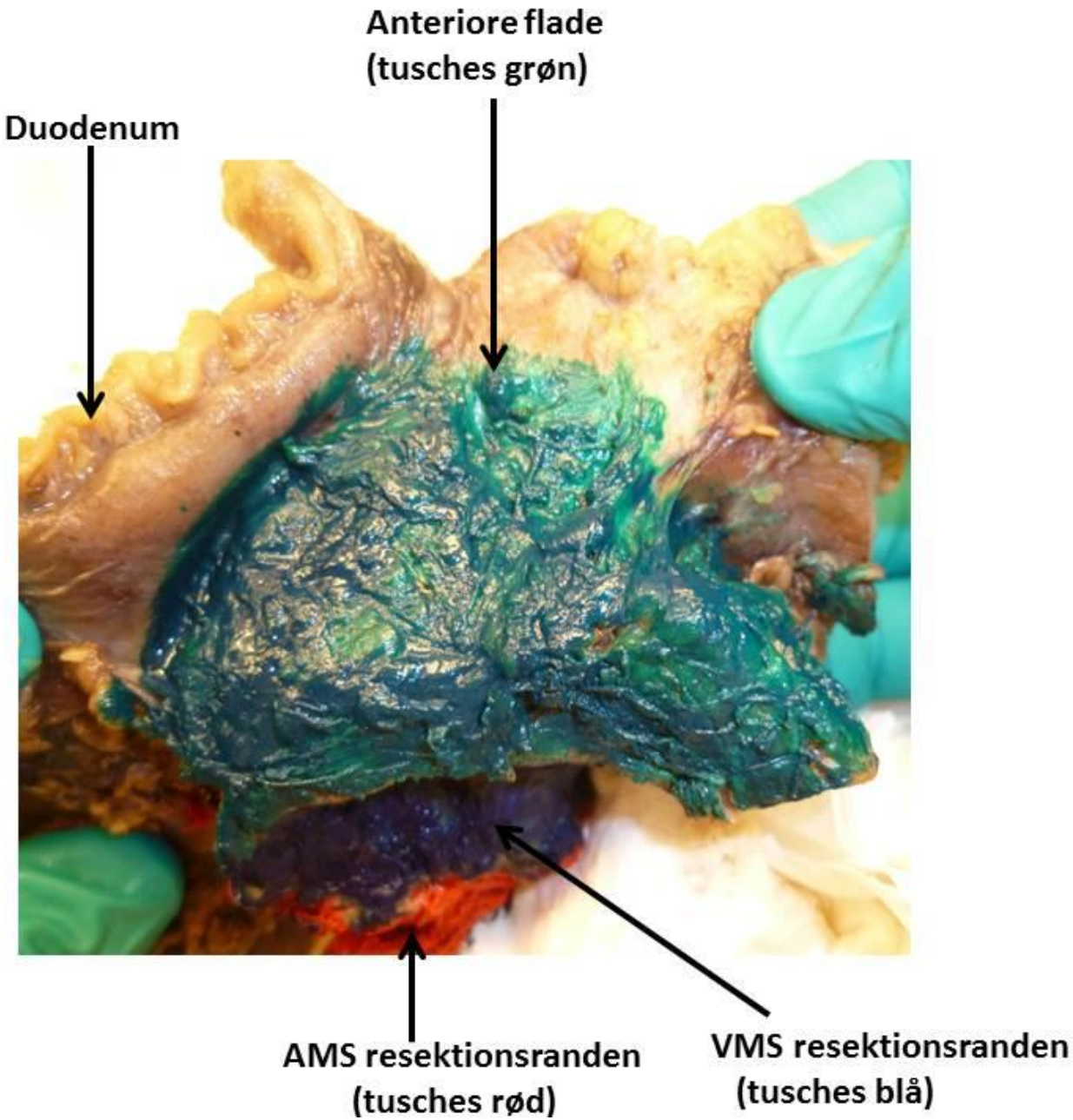
Anteriore flade
(tusches grøn)
Duodenum
AMS resektionsranden
(tusches rød)
VMS resektionsranden
(tusches blå)

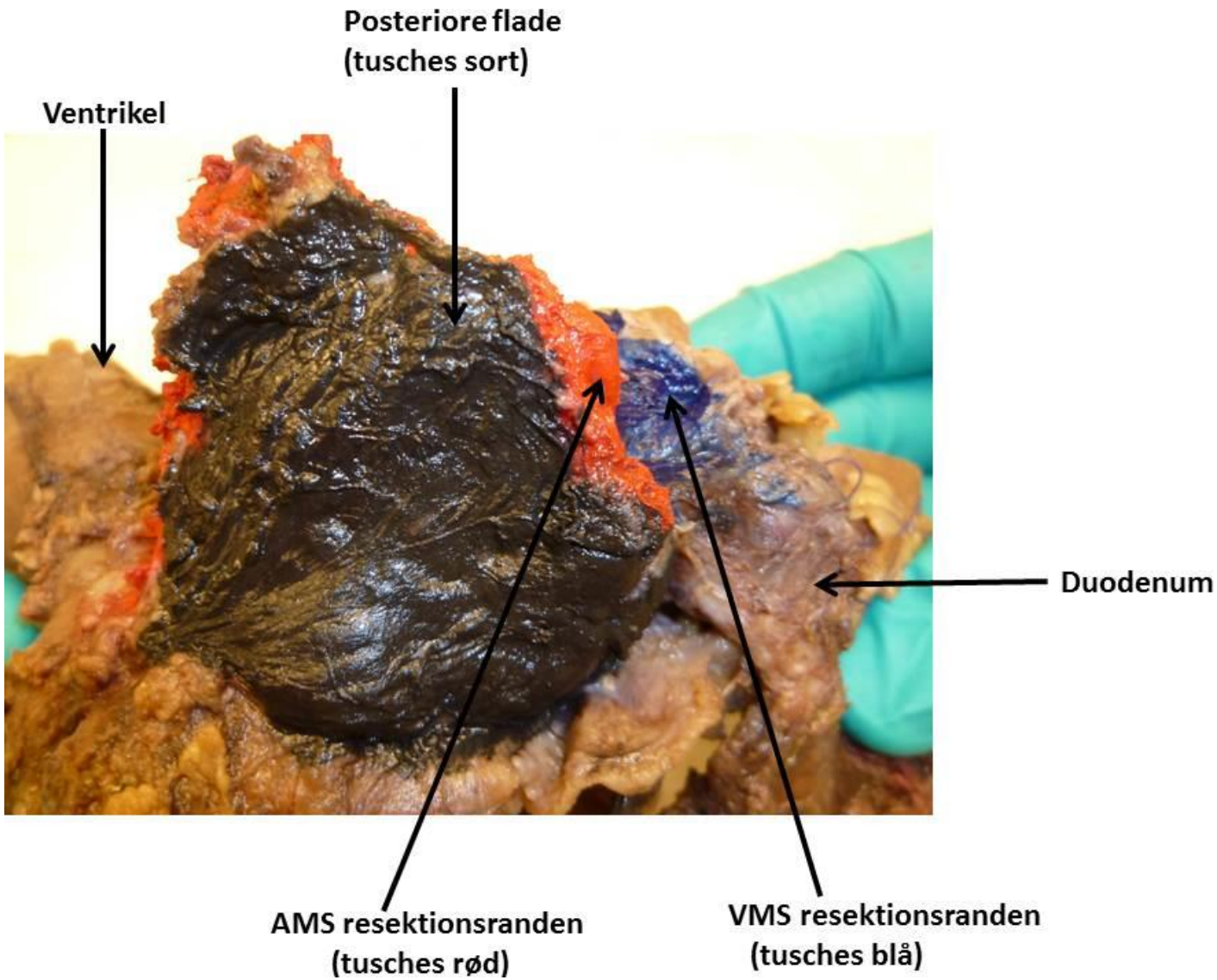
Posteriore flade
(tusches sort)
Ventrikel
Duodenum
AMS resektionsranden
(tusches rød)
VMS resektionsranden
(tusches blå)

Rigshospitalet

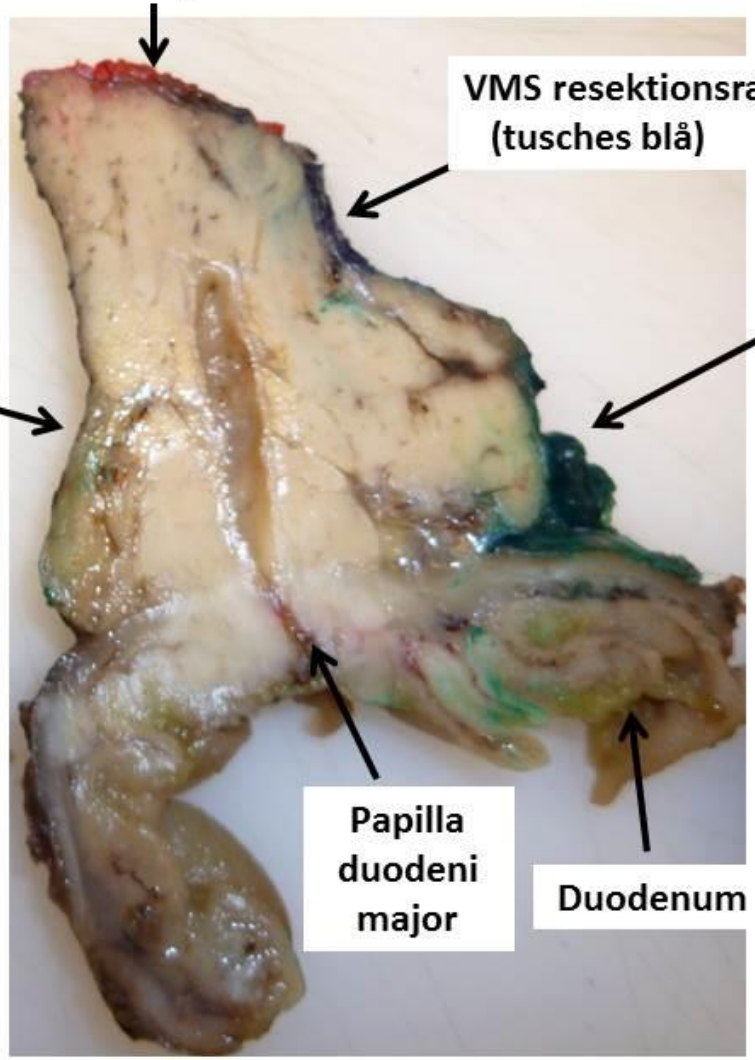

Udskæring

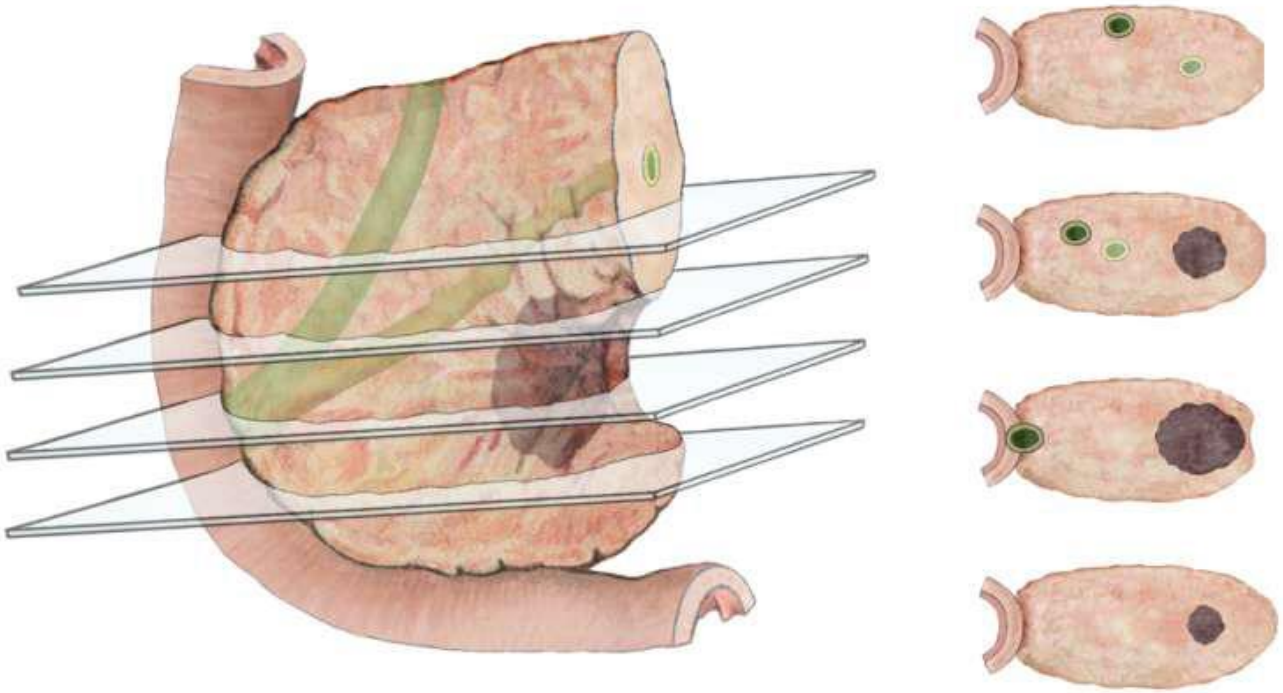

Udskæring

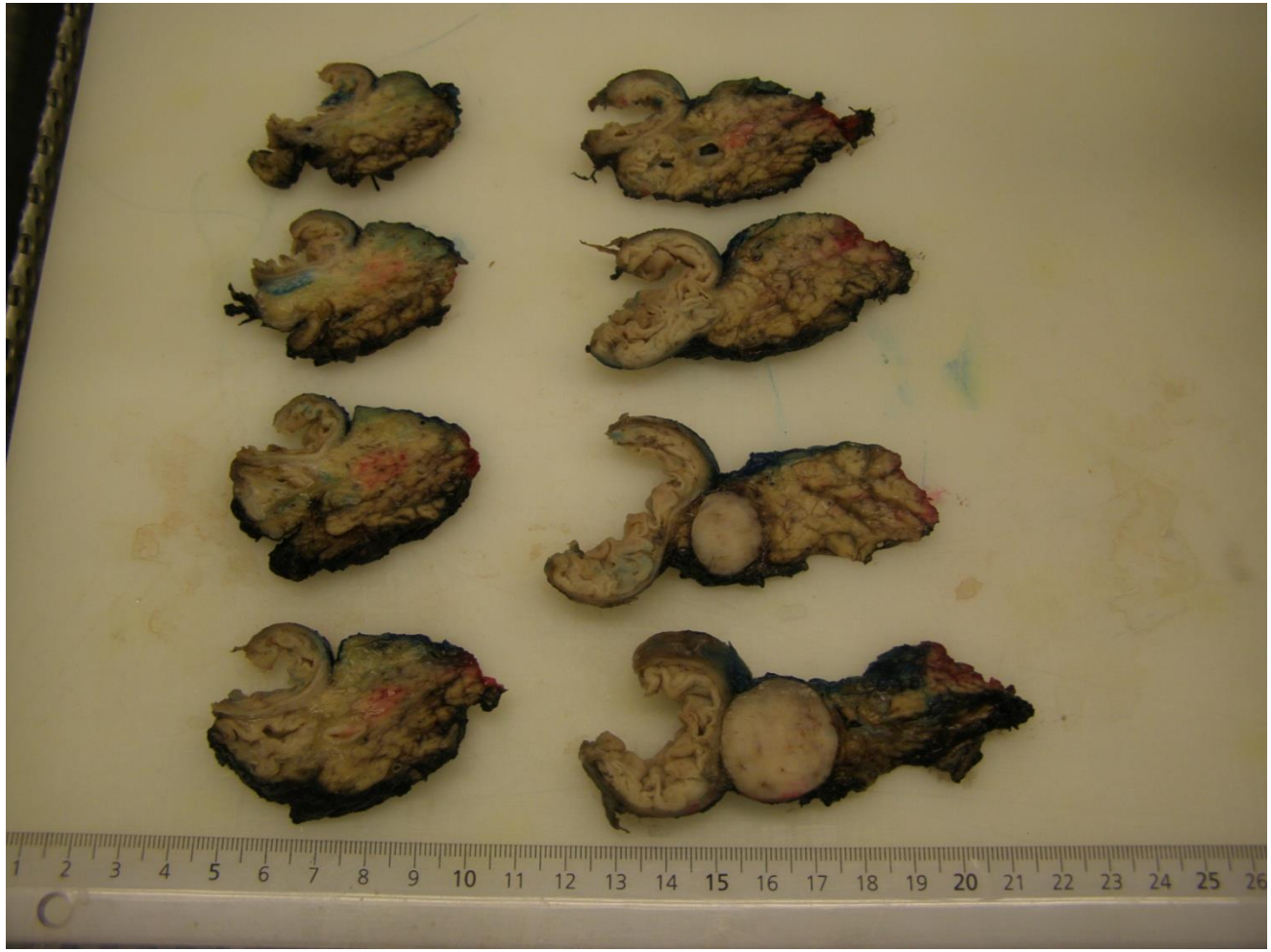

Rigshospitalet

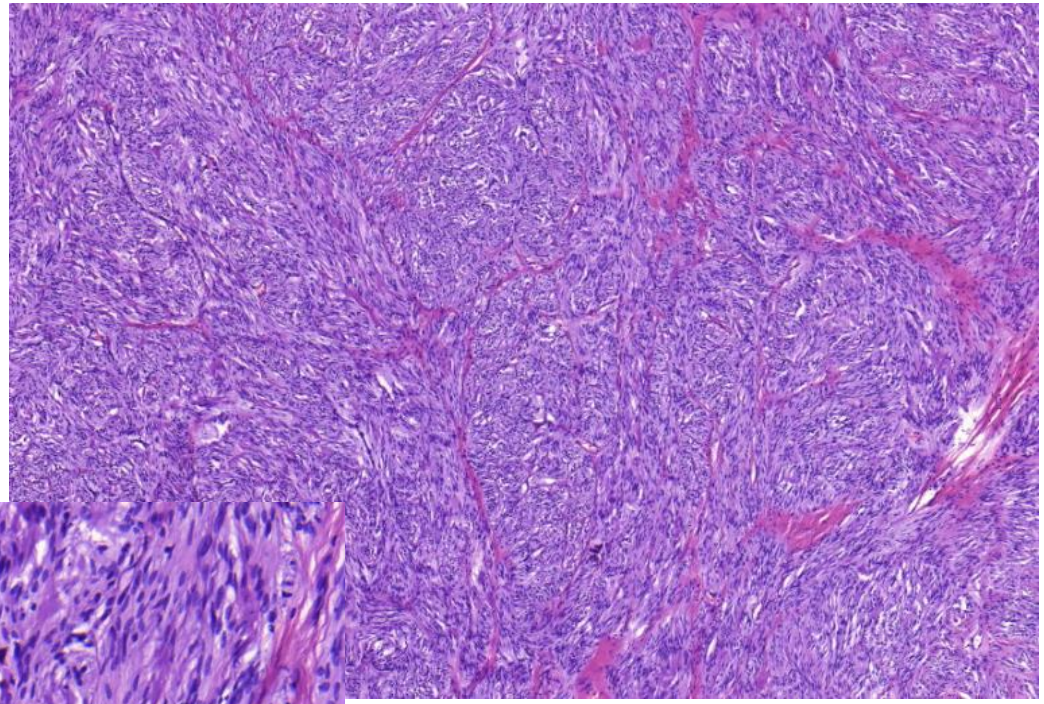

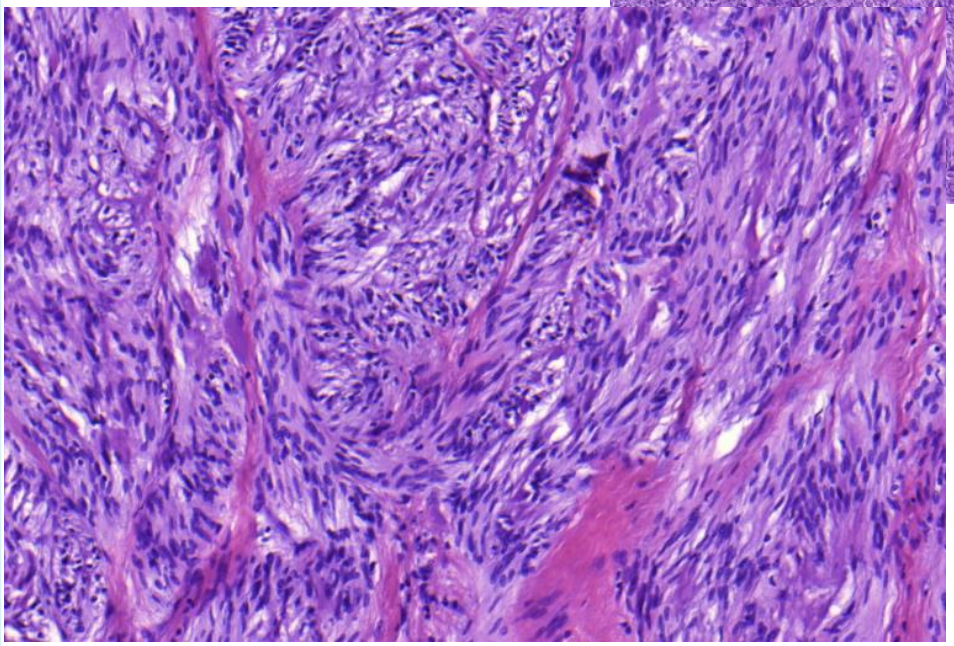

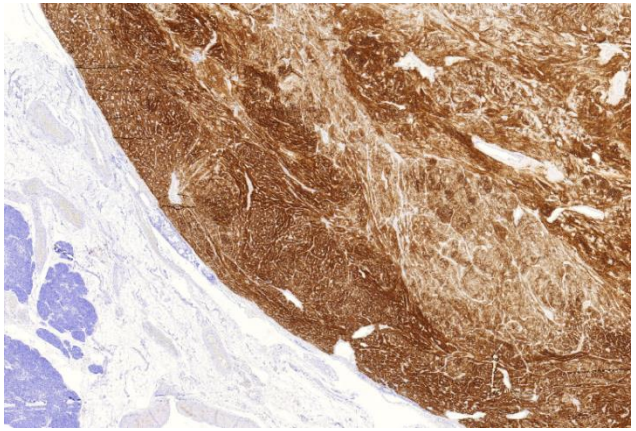

En-bloc vene resektion

Indvækst i v. mesenterica

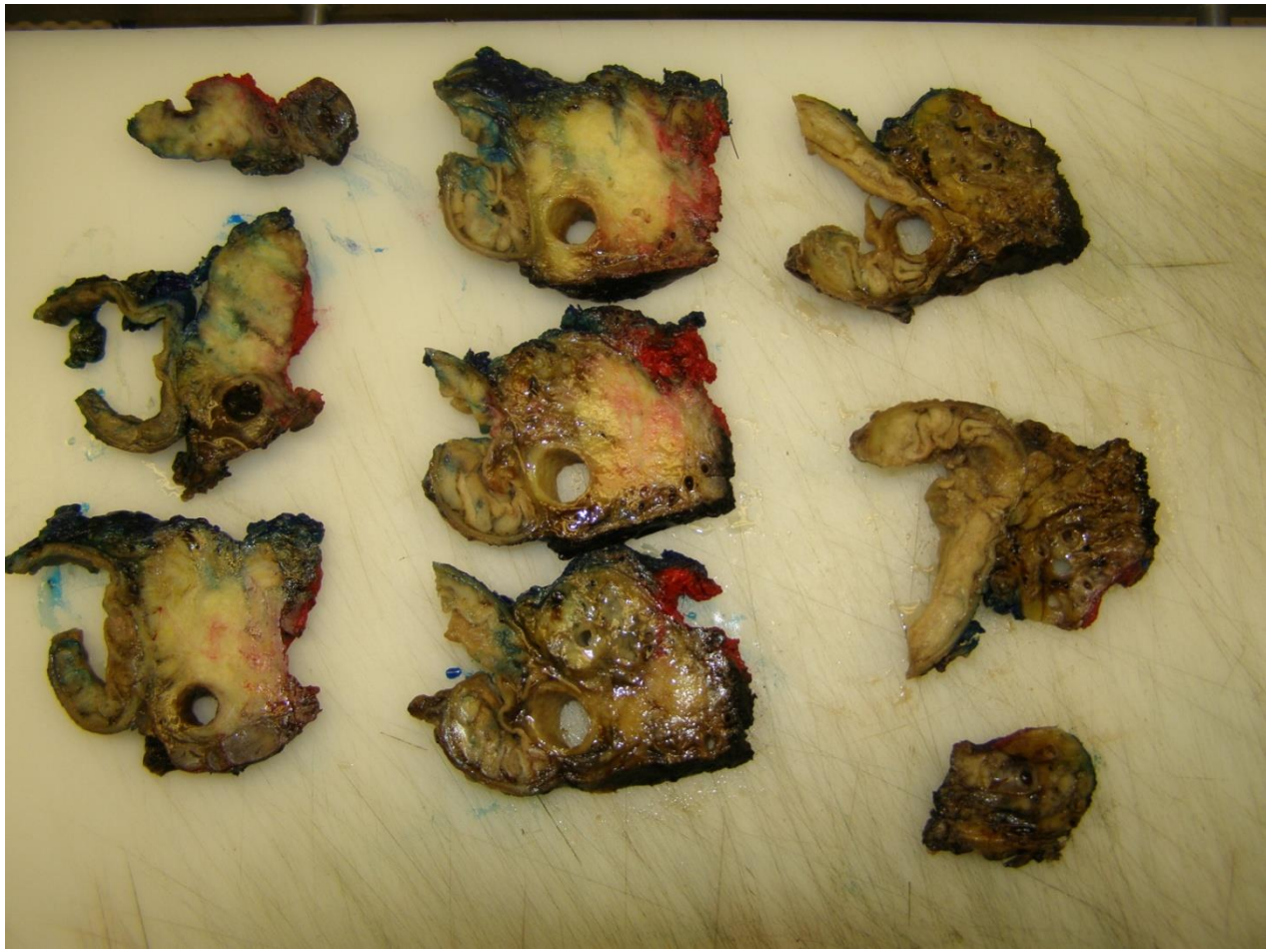

Veneindvækst

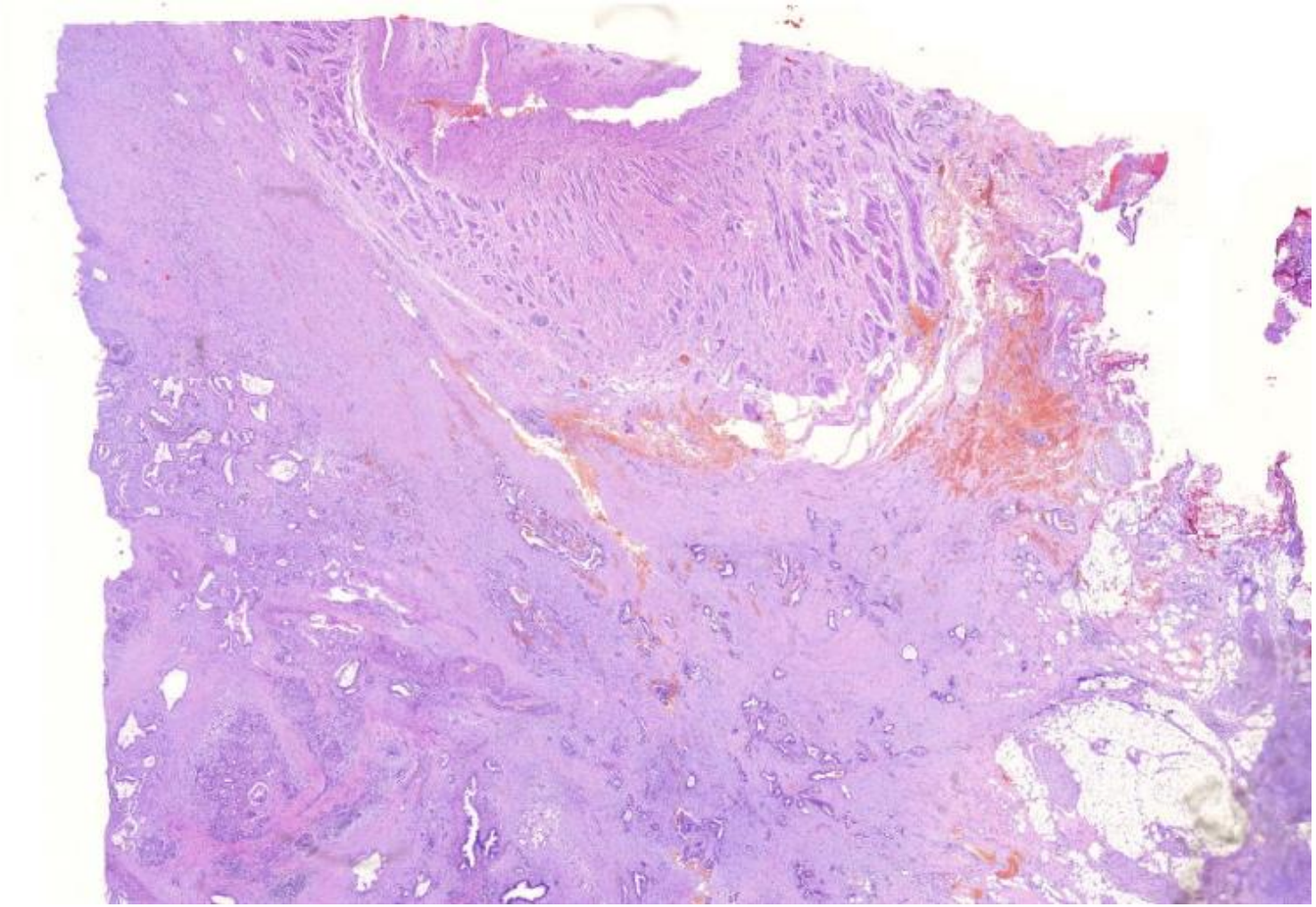

Duktalt adenokarcinom

- Patologi
  - Makroskopi
    - Dårligt afgrænset (størrelse svær at måle)
    - Grynet, hård, gråhvid masse
    - Infiltrerer lokalt
    - I avancerede tilfælde kan det være svært at bestemme tumors primære udgangspunkt – pancreas, ampulla Vateri eller ductus choledochus
    - Lokalisation
      - > 60% i caput
      - > 15% i corpus
      - > 5% i cauda
      - > 20% diffuse

Duktalt adenokarcinom

- Patologi - mikroskopi
  - Overordnet morfologi
    - Enkeltliggende tubulære strukturer
    - Udtalt desmoplastisk reaktion
    - Mucinproduktion specifik for den duktale oprindelse
    - Atrofi, kronisk inflammation, fibrose og duktal dilatation kan ses i den øvrige del af pancreas
  - Perineural vækst
    - Ses i 90% af tilfældene
    - Tumor invaderer langs nerven, typisk med højere differentierede duktale strukturer
    - Forårsager smerter i ryggen
    - Indikerer dårlig prognose
  - Karinvasion
    - Ses i 50% af tilfældene

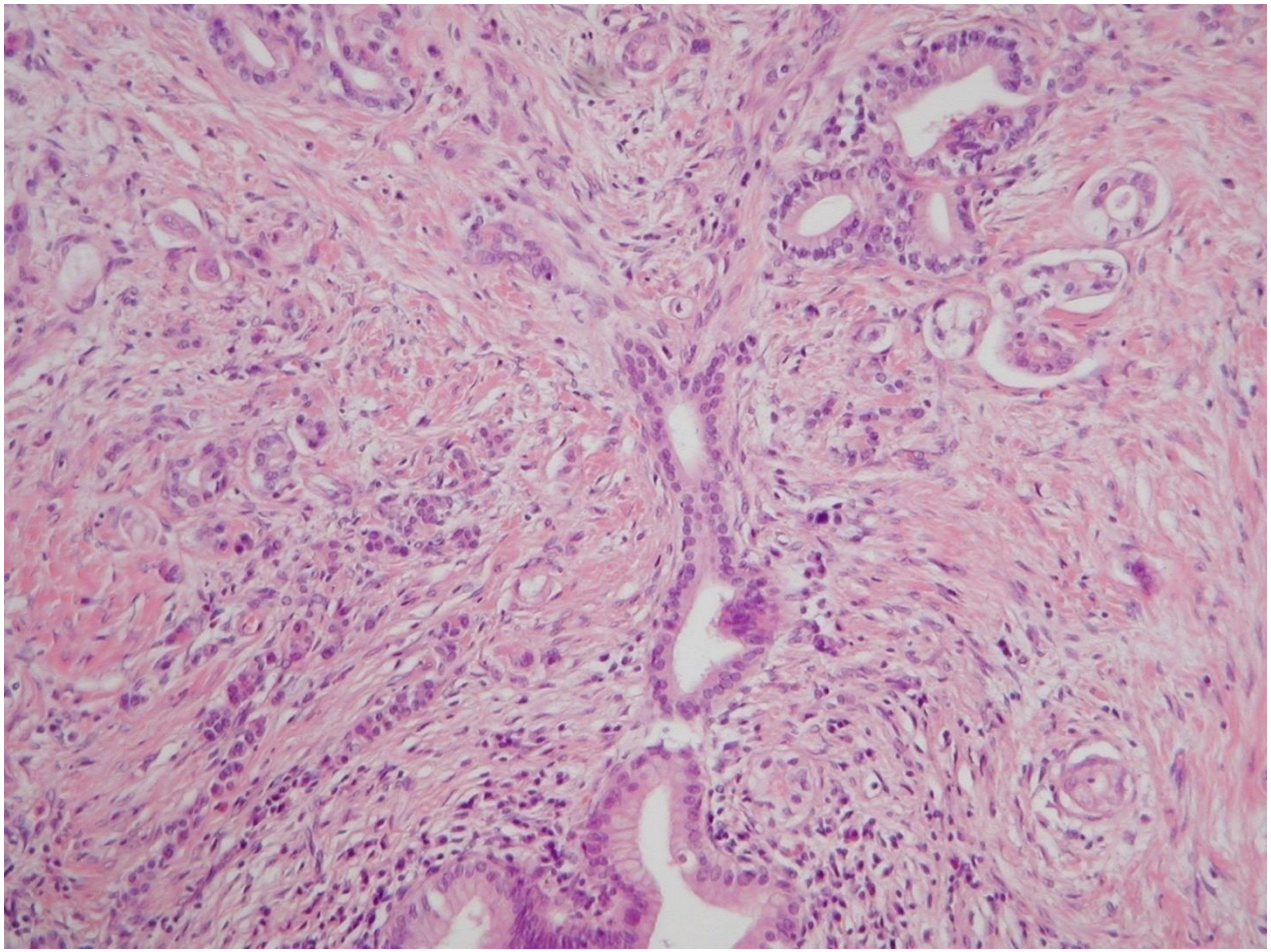

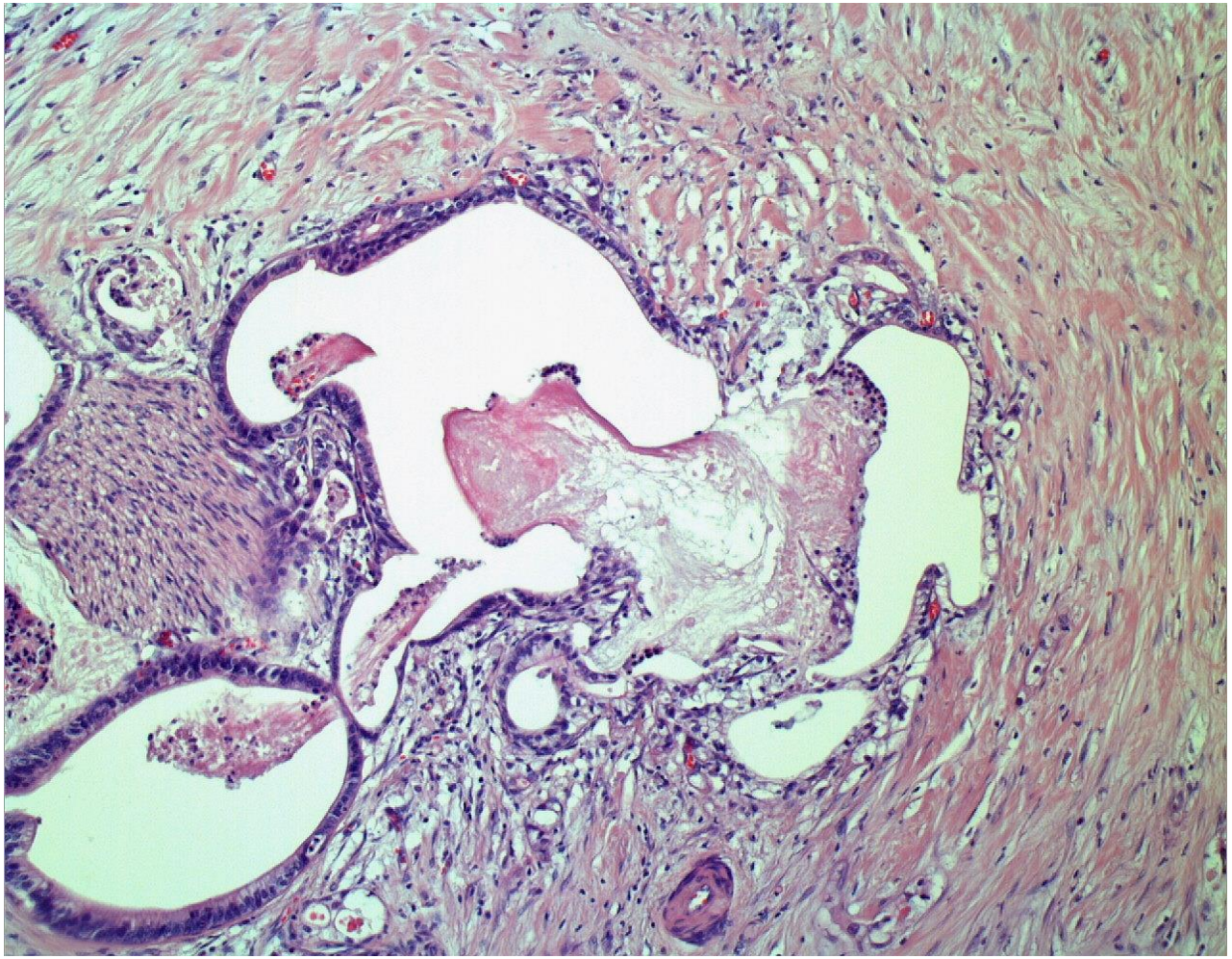

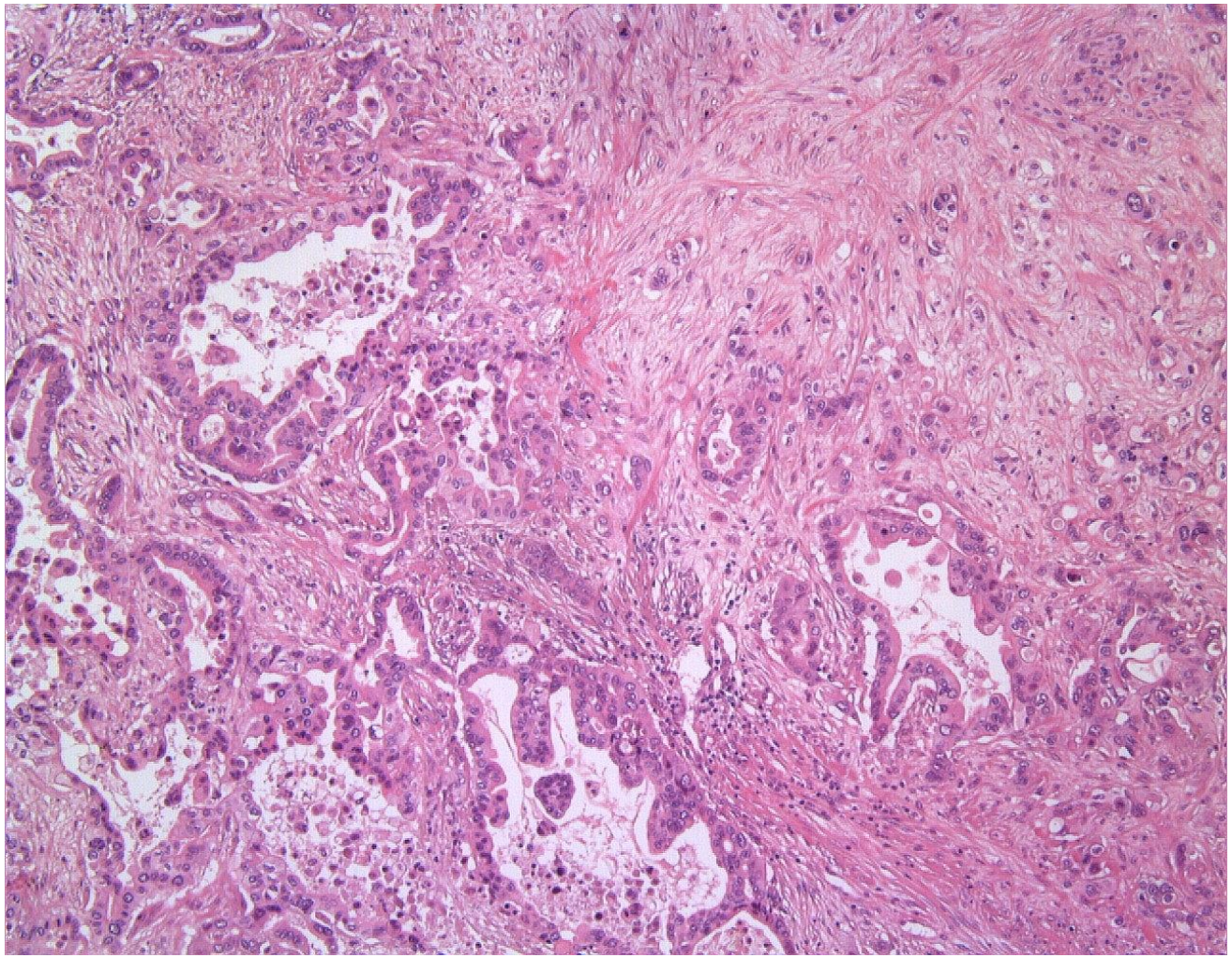

Rigshospitalet

Mixed Neuroendocrine Neoplasms (MINEN)

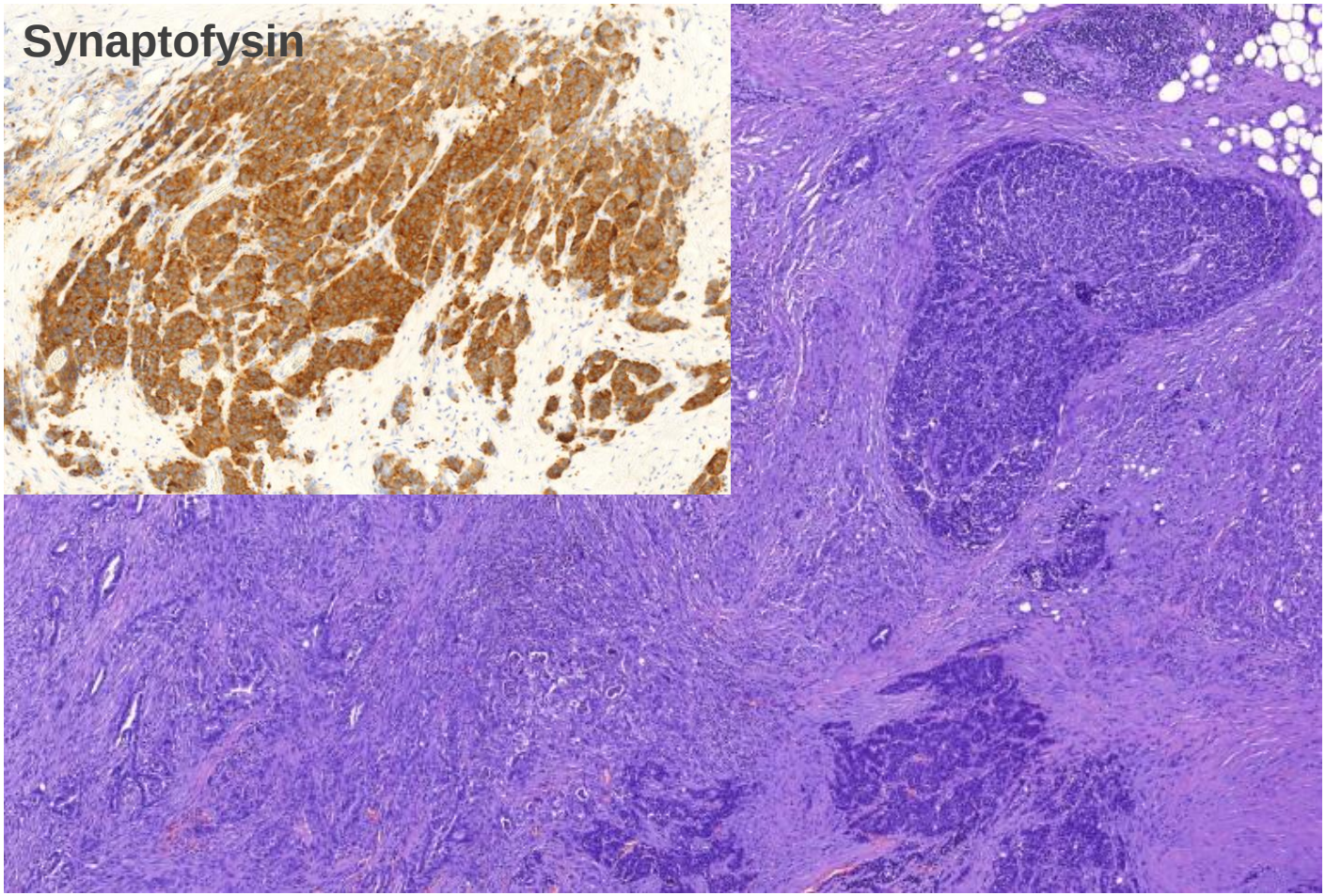

Immunhistokemi

- Positive farvninger
  - MUC1, MUC5AC, MUC6
  - Cytokeratin 7, 8, 18 og 19
  - mCEA
  - P53
  - CA125
  - S100P
  - Maspin
  - IMP3
- Negative farvninger
  - MUC2
  - CK20
  - CDX2
  - Tab af SMAD4 ses i 50% af tilfældene
  - VHL

Subtyper

- Epiteliale subtyper
  - Skvamøse type
  - Klassisk pancreatisk type
    - Progenitor type
      - > Immunogene progenitor type
      - > Rene klassiske progenitor type
    - Aberrantly Differentiated Endocrine Exocrine (ADEX-exokrin-lignende type)

- Stromale subtyper
  - Normal type
  - Aktiveret type

Ref; Molecular subtypes of pancreatic cancer
Eric A. Collisson1, Peter Bailey2, David K. Chang2,3 and Andrew V. Biankin, Nature reviews, 2019

Molekylære karakteristika

- Hyppigt mutationer i KRAS, TP53, CDKN2A, SMAD4
- Defekter i DNA Damage Respons (DDR), f.eks. BRCA-gener
  - Platinbaseret kemoterapi
  - PARPi behandling (poly(ADP-ribose) polymerase inhibitors)
- dMMR/MSI
  - Ca. 1-2% af PDAC
  - Immunterapi, Pembrolizumab

  - Andre lavfrekvente potentielt ”actionable targets” som BRAF, HER2, KRASwt

Duktalt adenokarcinom

- Behandling
  - Kurativ
    - Distal pancreatectomi for tumorer i corpus/cauda
    - Whipple's operation (subtotal pancreaticoduodenectomi) for tumorer i caput/periampullært evt. med karresektion
  - Whipple perioperativ mortalitet ~ 2%
  - Palliativ behandling omfatter bypass operationer, strålebehandling og kemoterapi
  - Adjuverende kemoterapi med Gemcitabin

Pancreas cancer- ubehandlet forløb

- Median overlevelse 6 måneder
- 10% i live efter 1 år
- 5 års overlevelse 0.5%

- Blandt de cancertyper med dårligst prognose overhovedet

Pancreas cancer – resultat efter kurativ resektion

• Median overlevelse	1-2 år
• Pancreas cancer (5-års overl.)	20-25%
• Små periampullære cancere (5-års overl.)	35-40%

Duktalt adenocarcinom

- Prognose
  - 85% kan ikke opereres radikalt på diagnosetidspunktet (tumorindvækst i omkringliggende organer og kar)
  - 75% med T1 og T2 sygdom har metastaser i de regionale lymfeknuder på diagnosetidspunktet
  - Fjernmetastaser til lever, lunger, peritoneum, binyrer, knogler, lymfeknuder (metastaser i supraklavikulære lymfeknuder) kan være debutsymptom
  - Samlet 5-års overlevelse 2-4%
  - 90% dør indenfor det første år efter at diagnosen er stillet

Neoadjuverende behandling

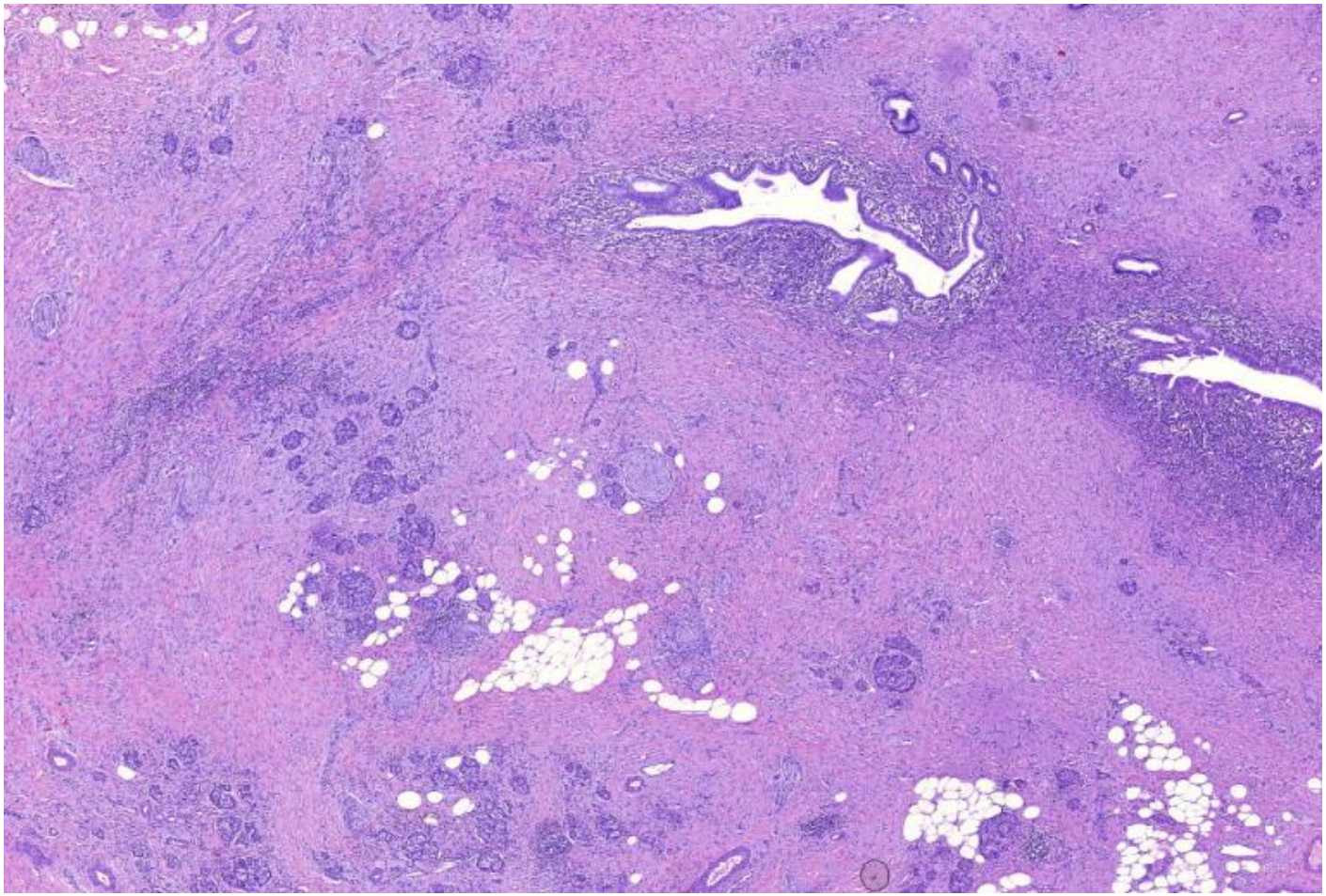

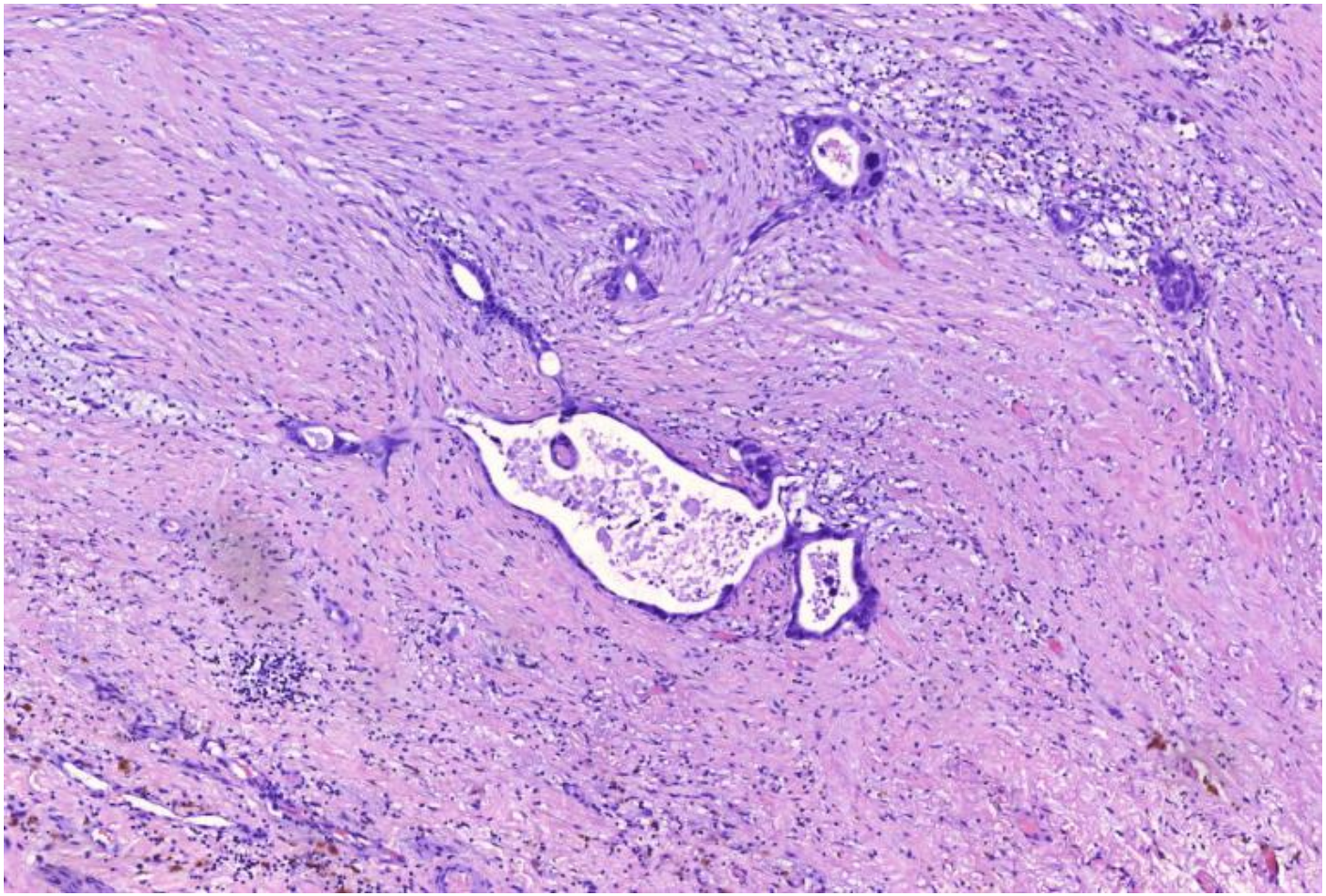

Precursor læsioner

- PanIN (pancreatic intraepithelial neoplasi)
  - Omfatter små gange, ikke ductus pancreaticus major
  - Læsionerne kan ikke ses makroskopisk eller (*radiologisk)*
  - <5mm
  - Gradinddeles
    - PanIN-1A
    - PanIN-1B
    - PanIN-2
    - PanIN-3
  - Gradering baseres på værste forandring

Rigshospitalet

Pancreatic Intraepithelial Neoplasia

PanIN 1a

PanIN 1b

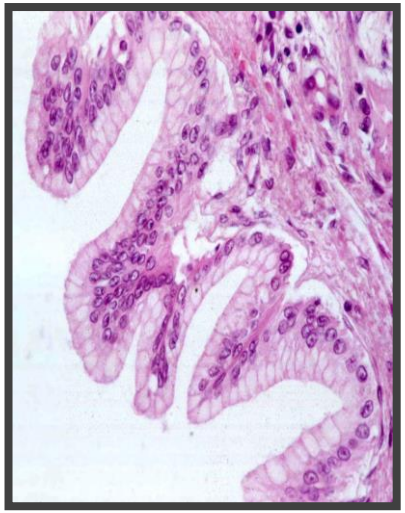

- Omfatter små gange
- Kan ikke ses makroskopisk
- <5mm

PanIN 2

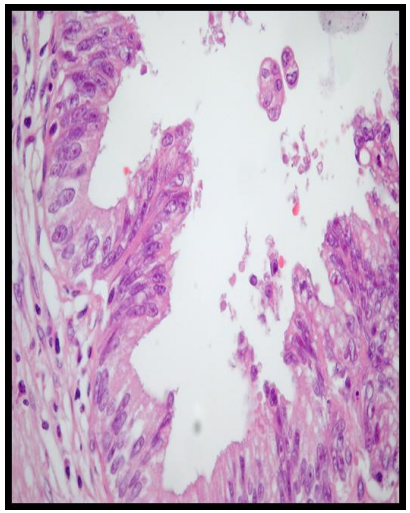

PanIN 3

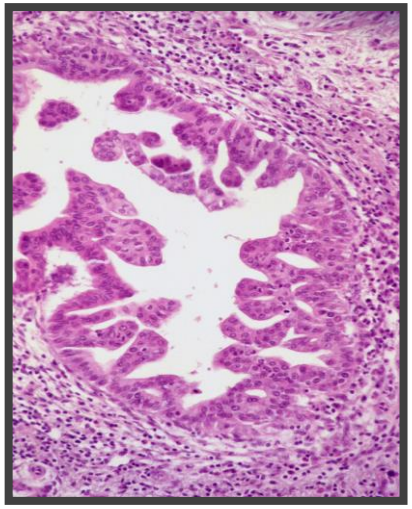

- Low grade neoplasi/dysplasi
  PanIN 1 og 2
- High grade neoplasi/dysplasi
  PanIN 3

Molekylære forandringer

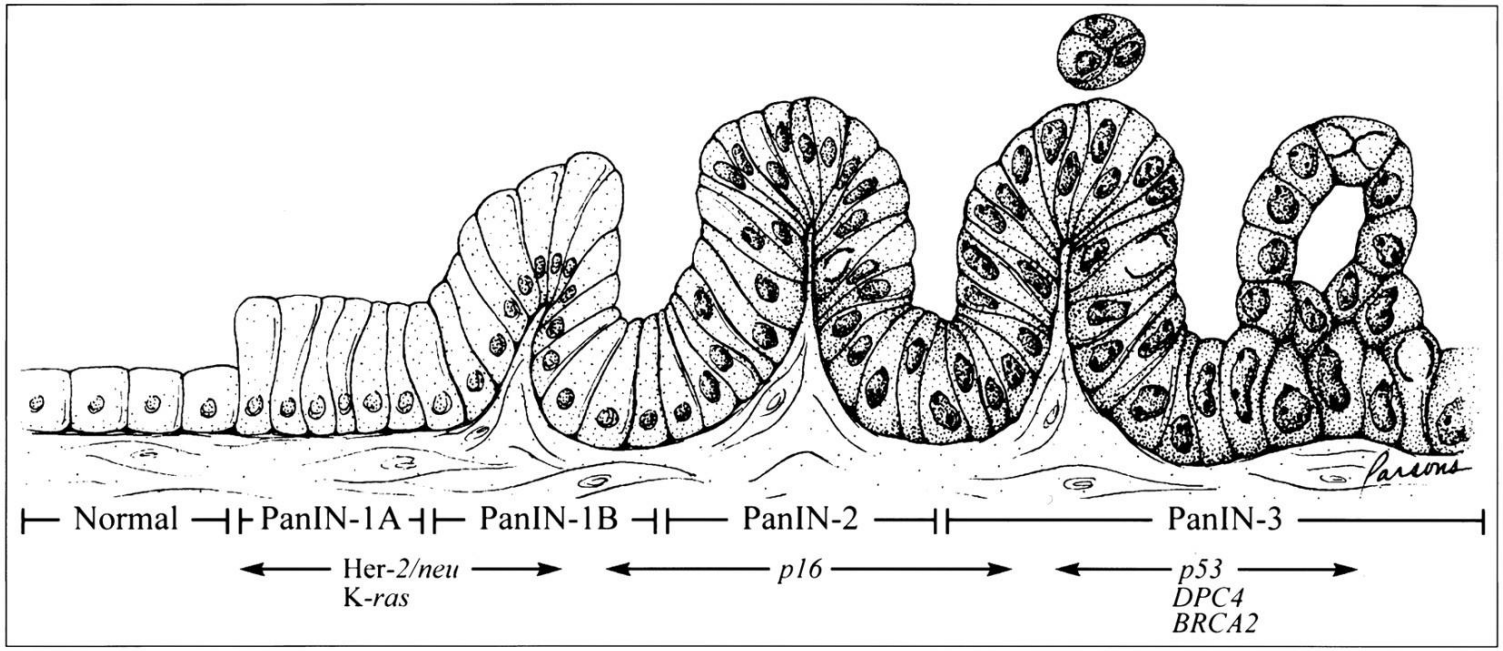

Acinær celle karcinom

- Klinik
  - Sjælden (1-2% af maligne tumorer i pancreas), men aggressiv tumor
  - M:K ratio 2:1, oftest voksne
  - 5-års overlevelse 10%
- Makroskopi
  - Oftest velafgrænsede
  - Bløde, flæskede, gullige til brunlige
  - Blødning og nekroser
- Mikroskopi
  - Celletæt, epithelial tumor, sparsomt stroma, ingen desmoplasi
  - Vokser solidt, i reder eller strenge, ofte med genkendelige acinære strukturer
  - Monotont cellebillede, acinære celler med granula, moderat atypi og ofte en del mitoser
- IHC
  - Trypsin
  - PAS (diastaseresistente granula)
  - Keratin 7, 8 og 18
  - Lipase

Acinær celle karcinom

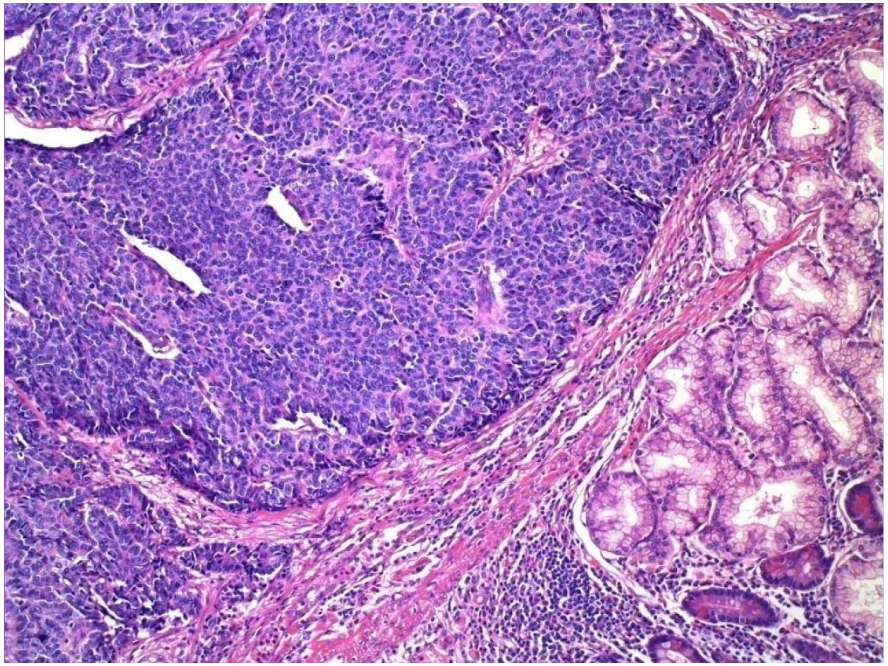

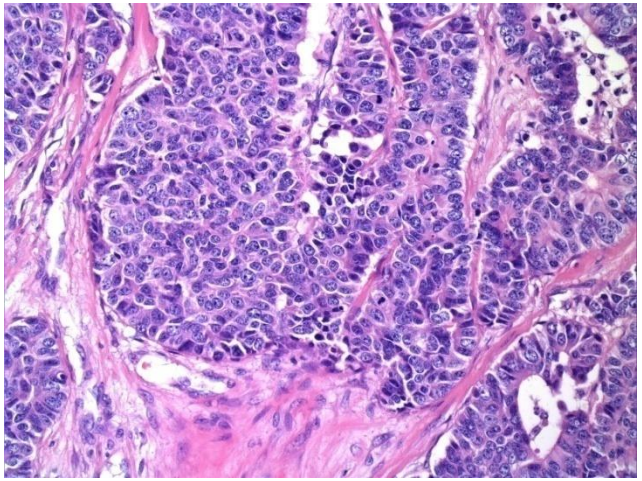

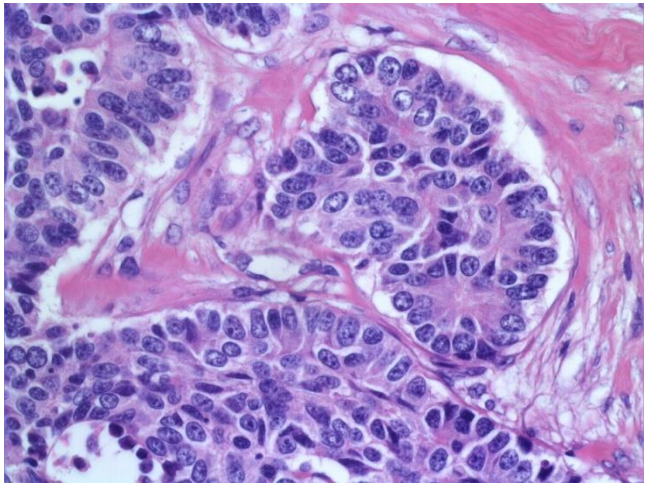

Solid-pseudopapillær neoplasi

- Sjælden
- Ses hos yngre kvinder
- Tilfældigt fund eller ukarakteristiske smerter
- 95% er benigne og kureres ved resektion
- Næsten alle tumorer har mutation i betacatenin genet → ekspression af proteinet

Solid-Pseudopapillær neoplasi

Solid-pseudopapillær neoplasi

- Mikroskopi
  - Variende udseende
  - Solide områder
    - Reder og strenge af ensartede, polygonal epitheloide celler adskilt af små kar
    - Pseudopapillære strukturer
    - Perivasculære ansamlinger af tumorceller
  - Degenerative forandringer
    - Skummakrofager
    - Kolesterol kløfter
    - Blødning
  - Andre histologiske karakteristika
    - Diastaseresitente PAS-positive cytoplasmatiske granula
    - Runde til ovale kerner med kløfter og indfoldninger

Histologi

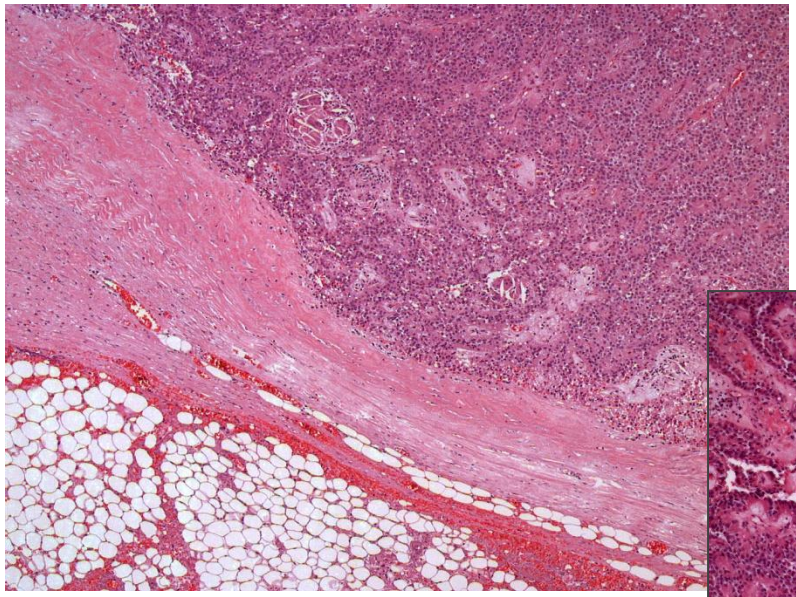

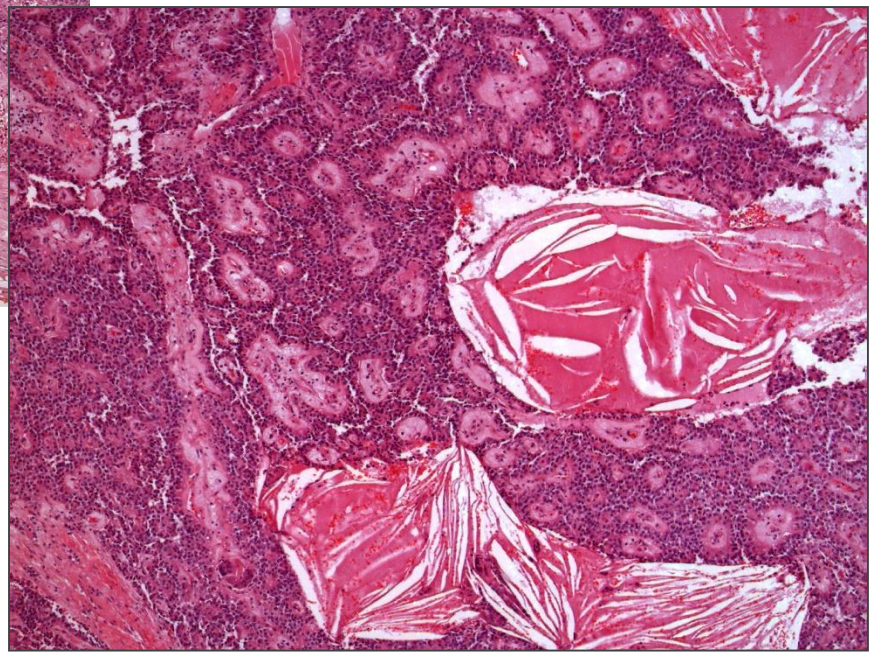

Immunhistokemi

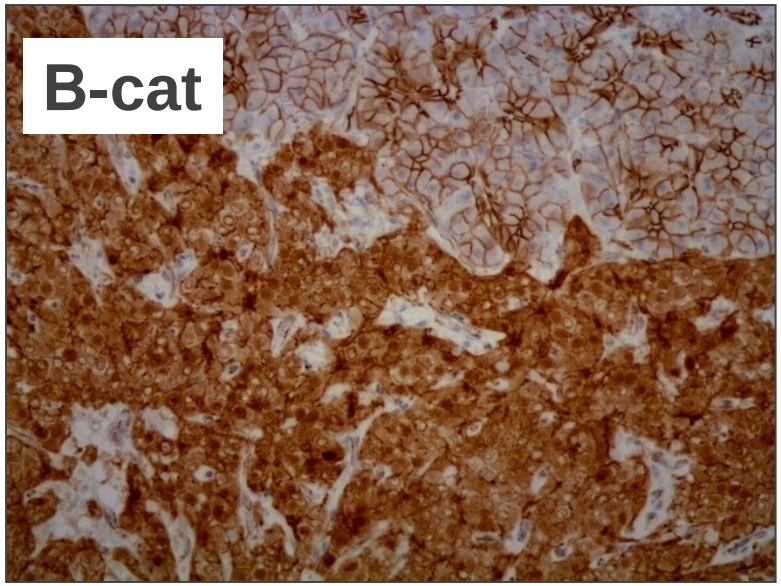

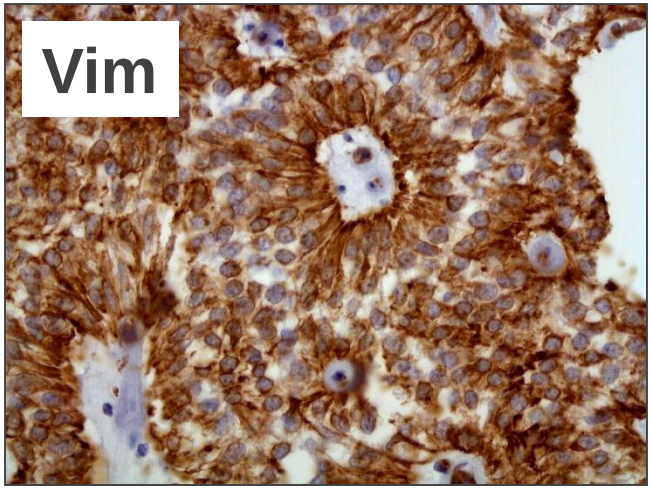

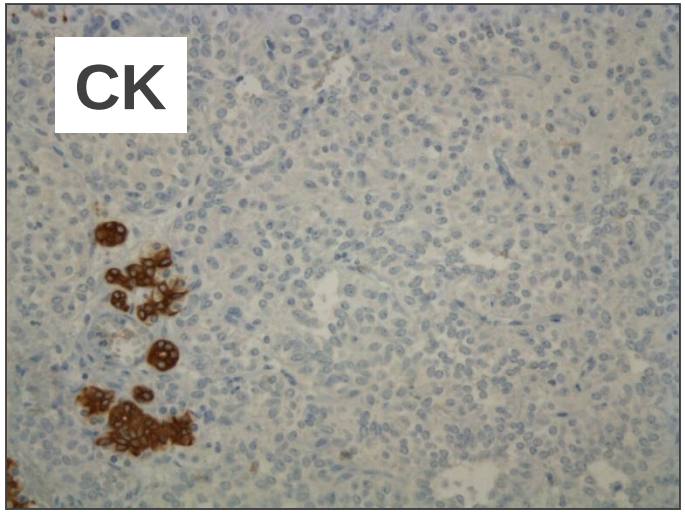

Cystiske tumorer

- Serøse cystadenomer
- Mucinøse cystiske neoplasier
- Intraduktale neoplasier
  - IPMN
  - ITPN

Cystiske tumorer

- Serøse cystiske tumorer
  - Serøst cystadenom
  - Mikrocystiske cystadenom er det hyppigste
  - Sjældne, F>M, , ass. Von Hippel-Lindau

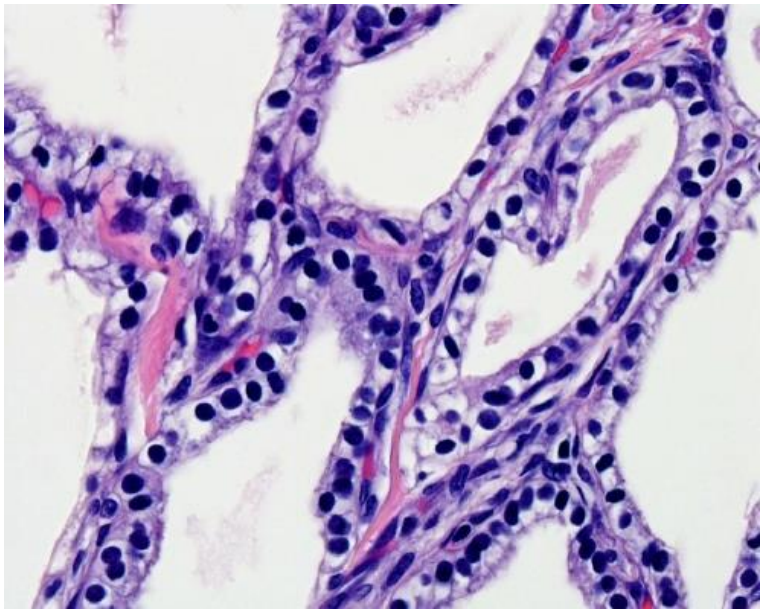

Rigshospitalet

Serøst cystadenom – Solid type

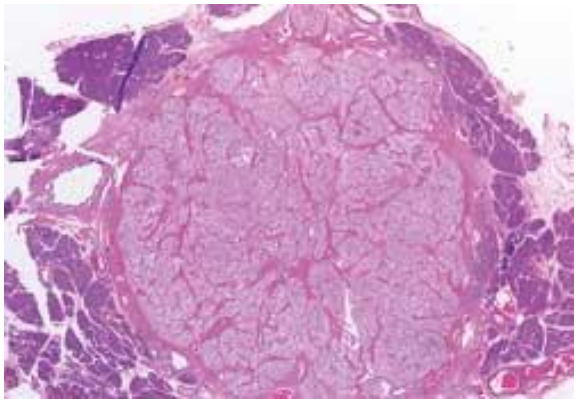

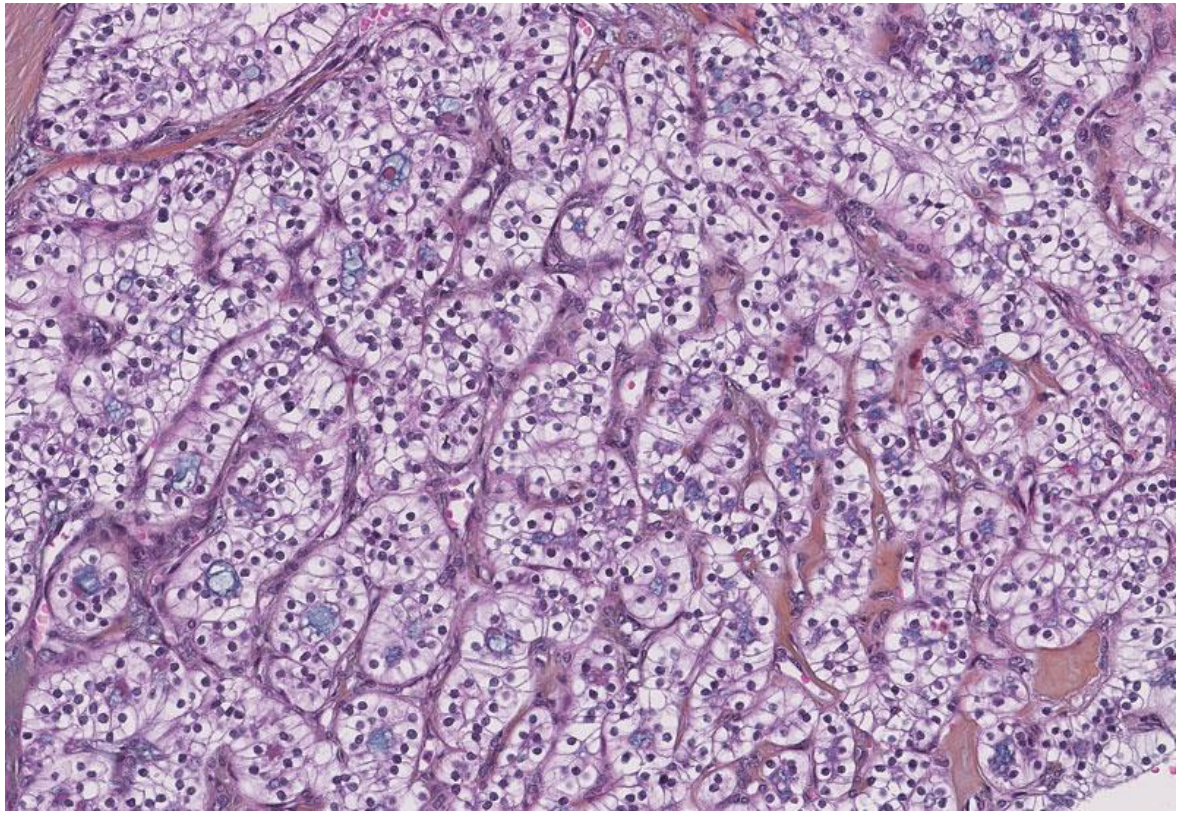

Cystiske tumorer

- Mucinøse cystiske neoplasier
  - Relativt hyppige, F>>M, corpus-cauda
  - Tykvæggede, multilokulære
  - Ovarie-lign. stroma
  - Epitel med low/ intermediær/ high grade dysplasi

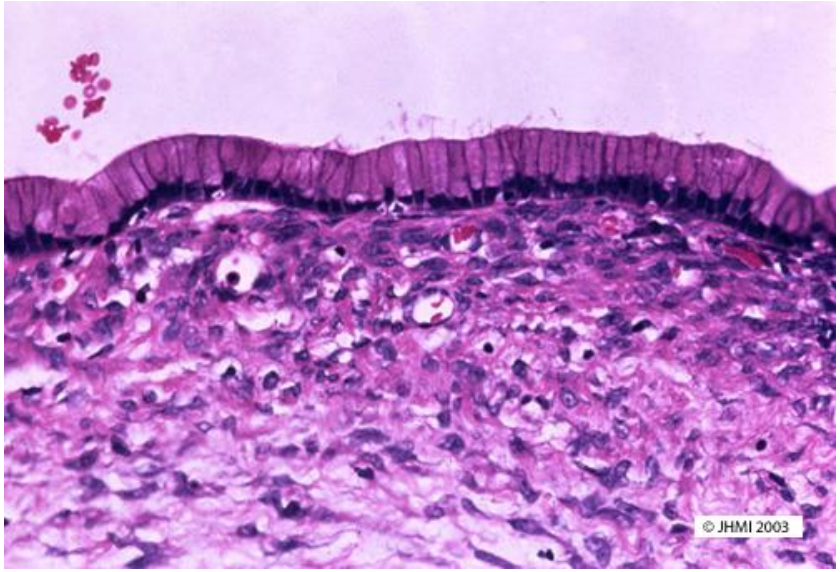

MCN

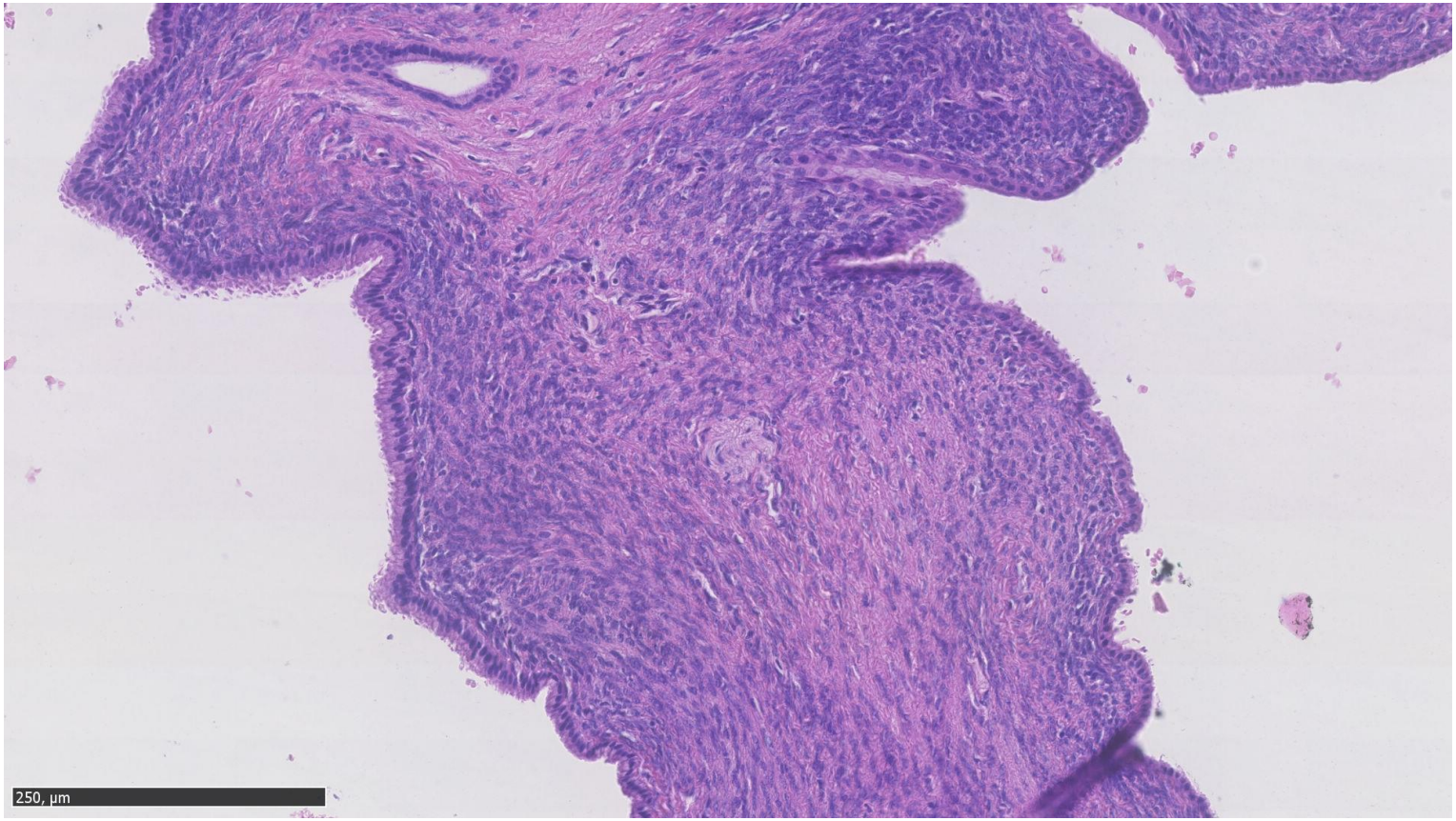

ER

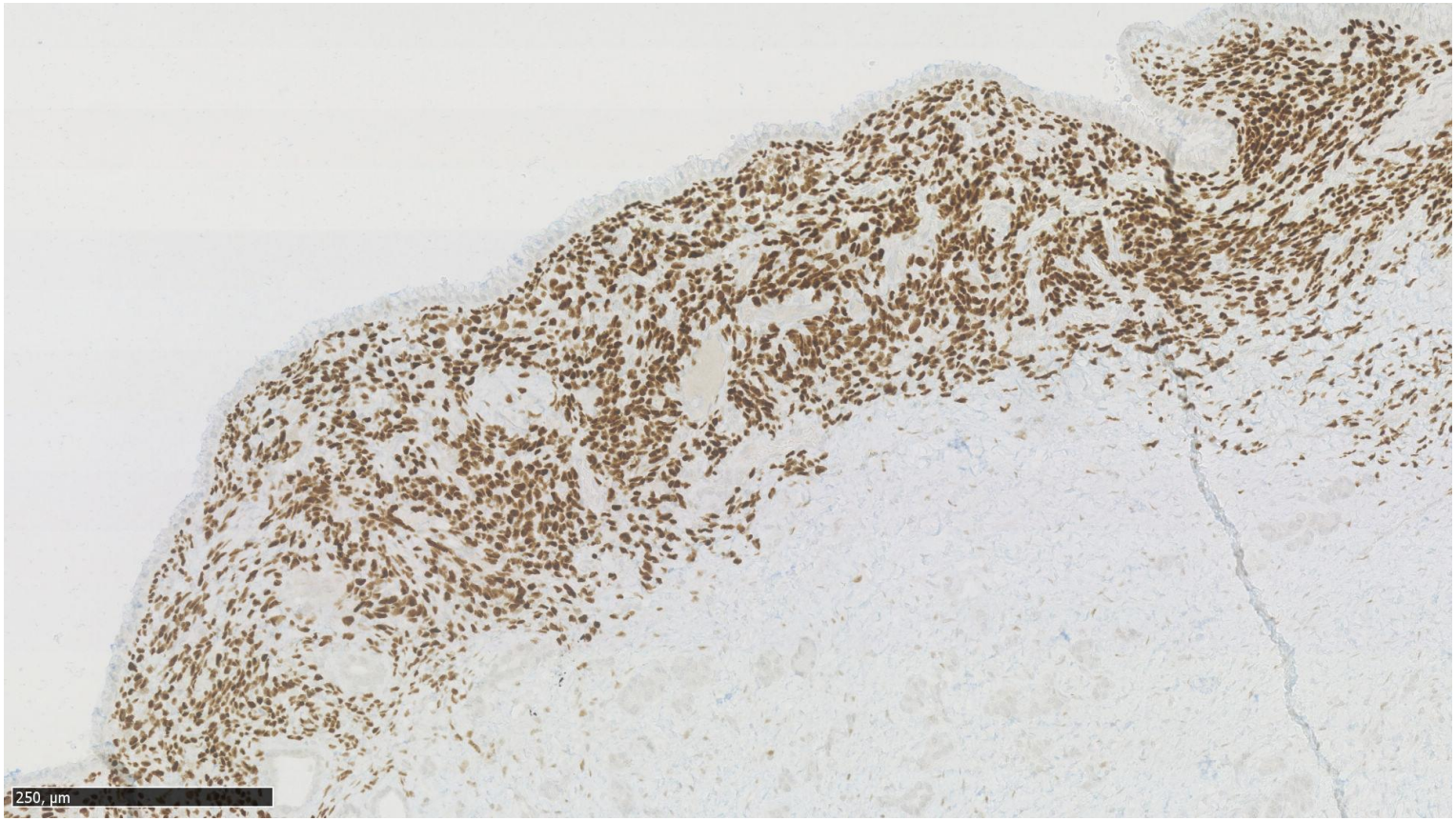

Inhibin

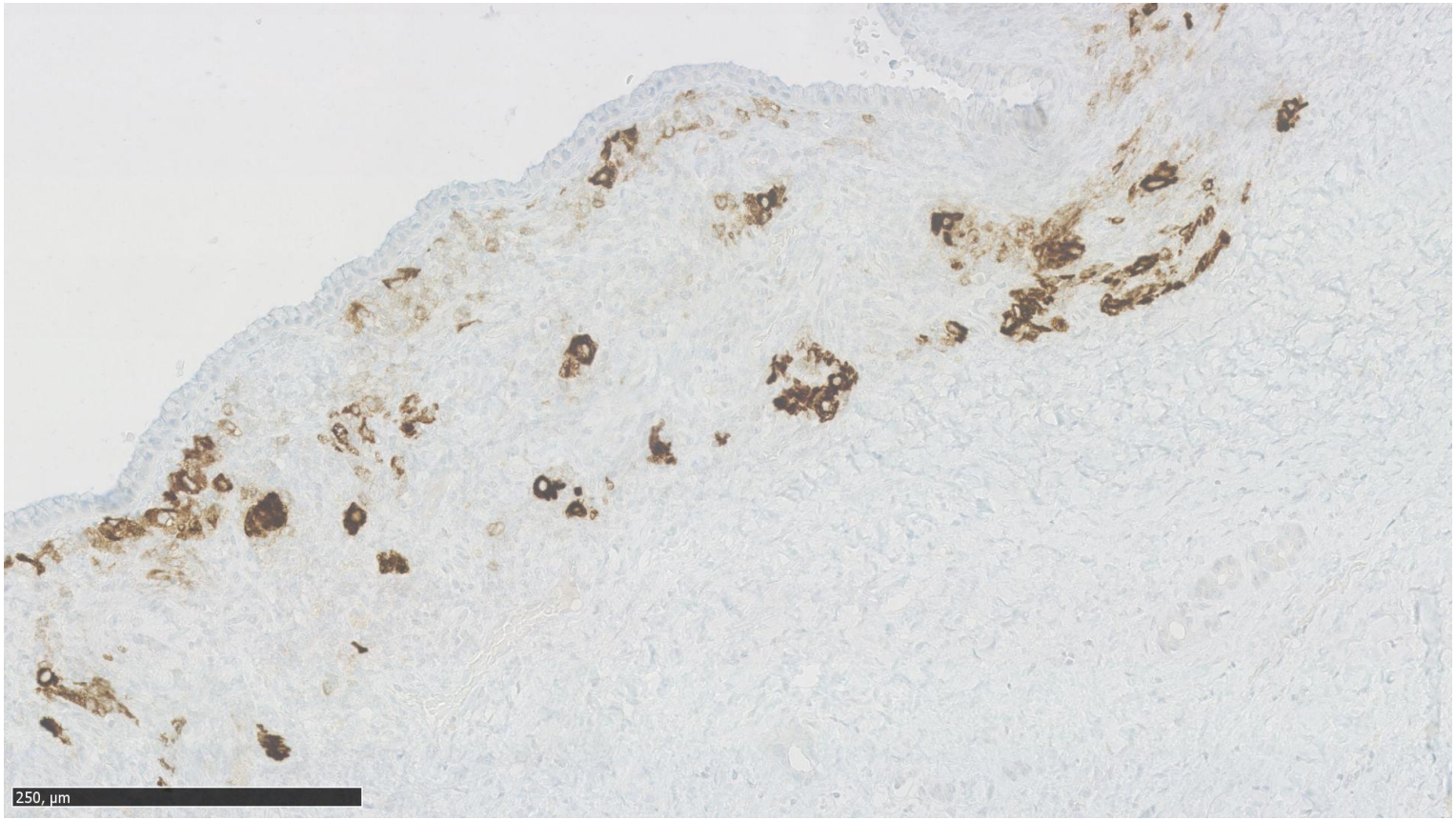

Cystiske tumorer

- ***Intraduktale papillære tumorer***
  - *Intraduktale papillære mucinøse neoplasier* ***(IPMN)*** og intraduktale tubulopapillære neoplasier (ITPN)
  - Hyppige
  - M>F, ældre, kommunikation med duct-systemet, caput
  - Ofte asympt.
  - Makroskopisk synlige forandringer, >/= 1 cm
  - Makroskopisk typisk cystisk dilateret ductsystem, papillære ekskresenser luminalt.
  - Papillære formationer, epitel med dysplasi, evt. invasive foci.

Morphologic classification of IPMN

Branch pancreatic duct

Diffuse main pancreatic duct

Segmental main pancreatic duct

Mixed (main & branch ducts)

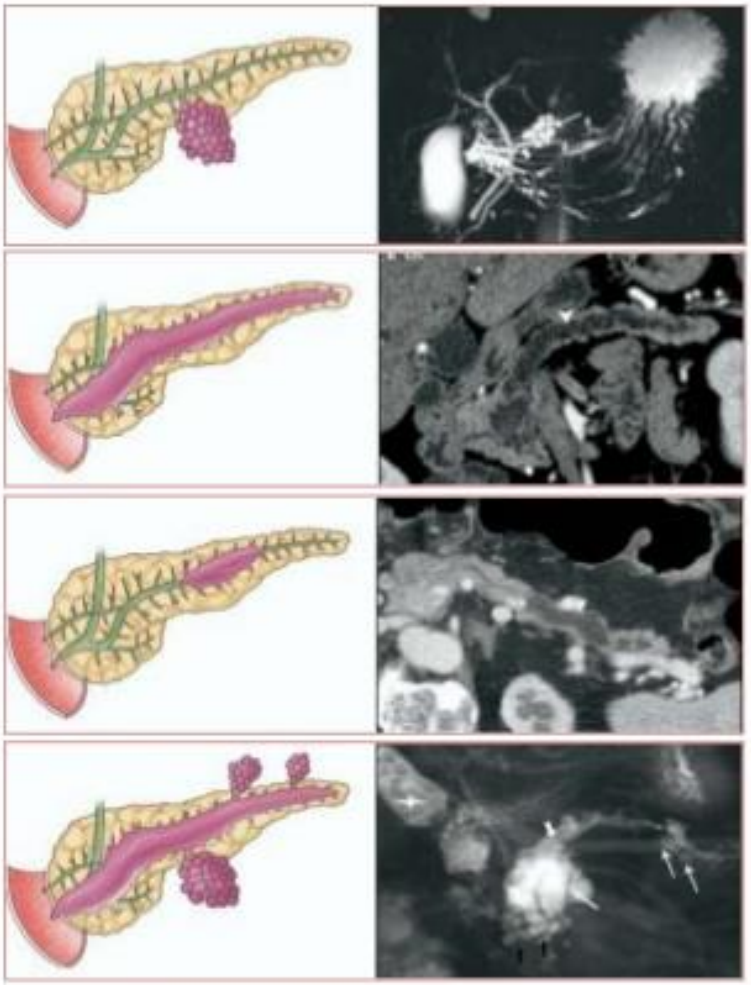

Sahani DV et al. Clin Gastroenterol Hepatol 2009; 7 : 259 – 269.

IPMN

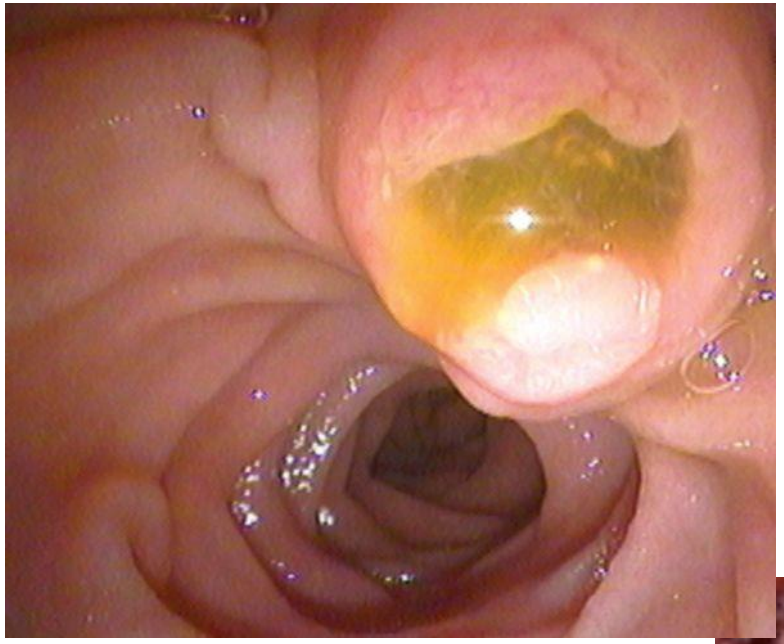

IPMN

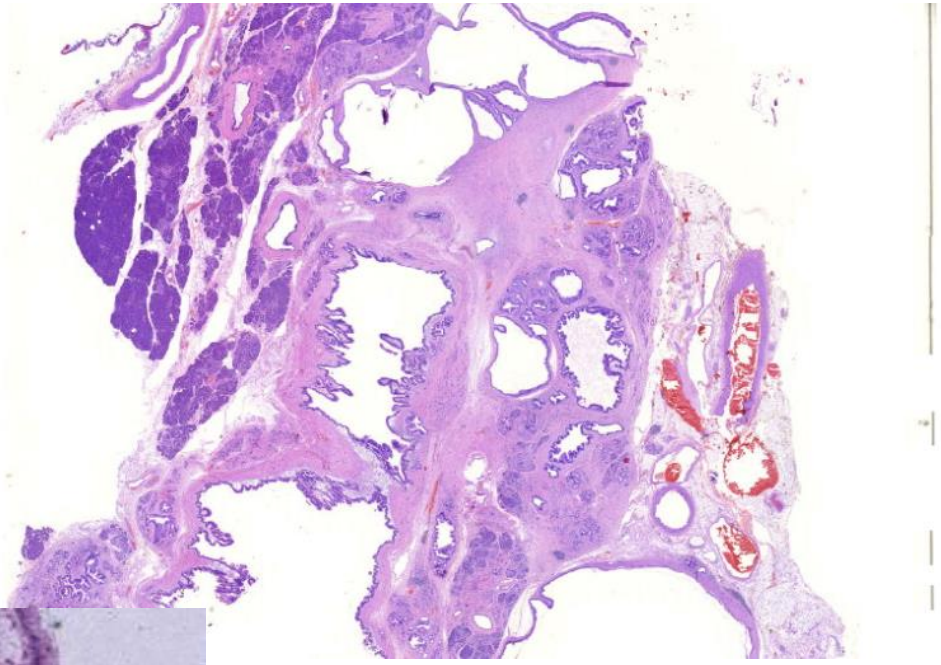

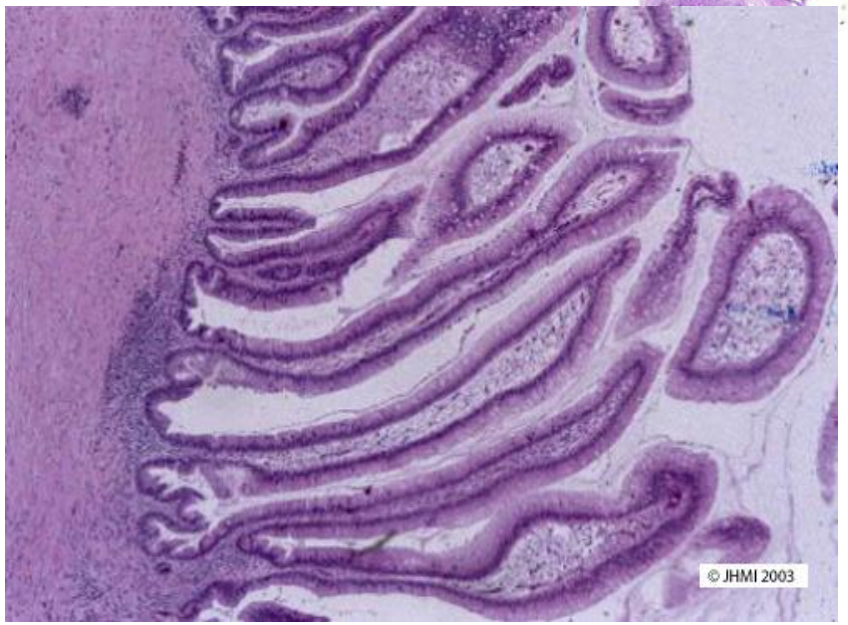

Epiteltyper

- Gastrisk (CK7, MUC5AC)
- Intestinalt (CK20, CDX2, MUC2, MUC5AC)
- Pancreatico-biliært (CK7, MUC1, MUC5AC, MUC6)
- Onkocytært (CK7, MUC5AC, MUC1, MUC6)

- Fænotypen og dysplasigrad har prognostisk betydning
- Ca. 30 % har invasive foci
  - Indstøbes rigeligt!

Cystiske tumorer- oversigt

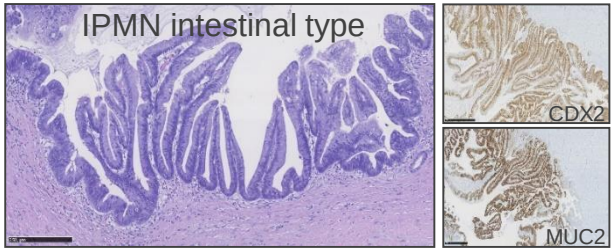

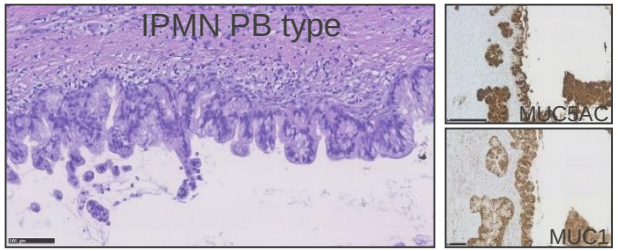

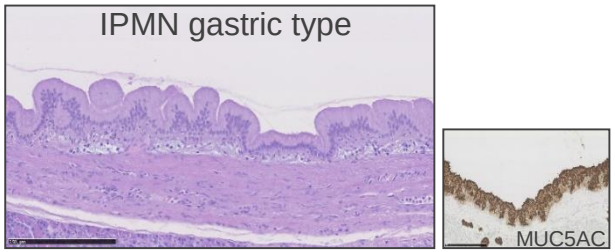

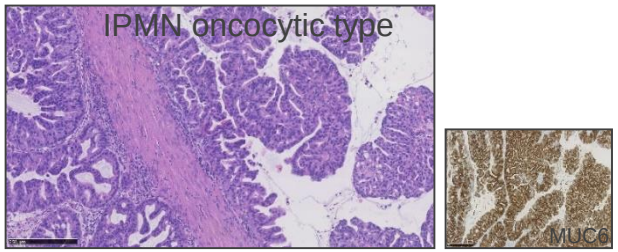

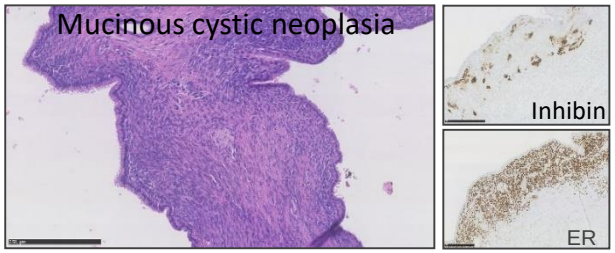

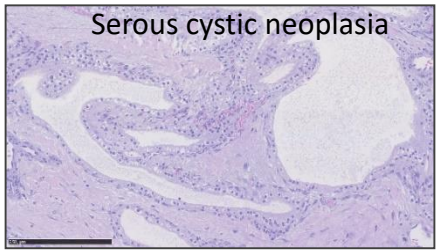

Rigshospitalet

Anbefalede guidelines for resektion af IPMN

Ref; Gut. 2018 May;67(5):789-804. doi: 10.1136/gutjnl-2018-316027. Epub 2018 Mar 24.
European evidence-based guidelines on pancreatic cystic neoplasms.
European Study Group on Cystic Tumours of the Pancreas.

Absolute indications	Relative indications
Positive cytology for malignancy/HGD	Grow-rate ≥5 mm/year
Solid mass	Increased levels of serum CA 19.9 (>37 U/mL)*
Jaundice (tumour related)	MPD dilatation between 5 and 9.9 mm
Enhancing mural nodule (≥5 mm)	Cyst diameter ≥40 mm
MPD dilatation ≥10 mm	New onset of diabetes mellitus
	Acute pancreatitis (caused by IPMN)
	Enhancing mural nodule (<5 mm)

IPMN

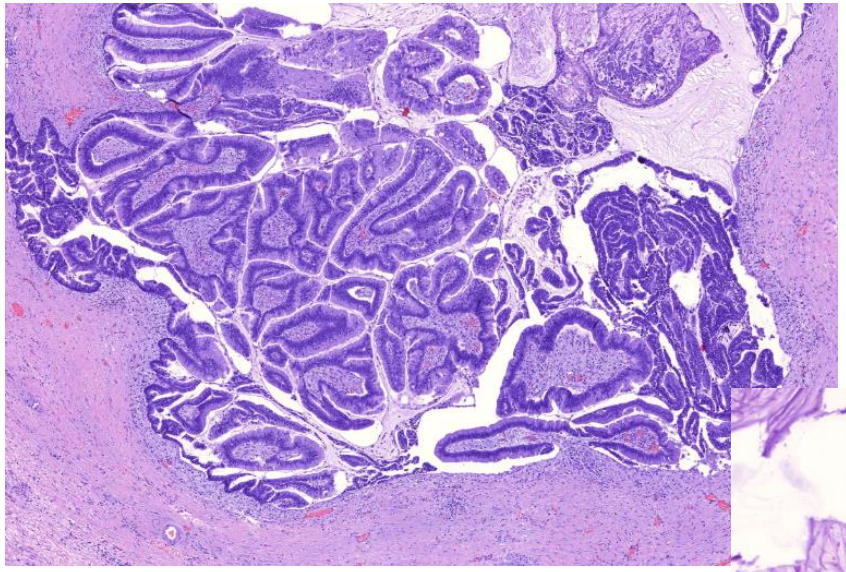

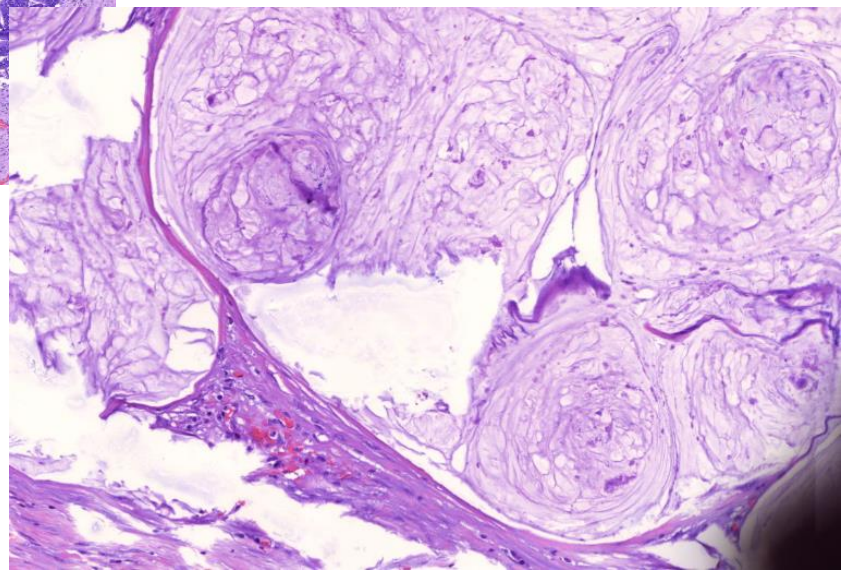

Mucinøst adenokarcinom

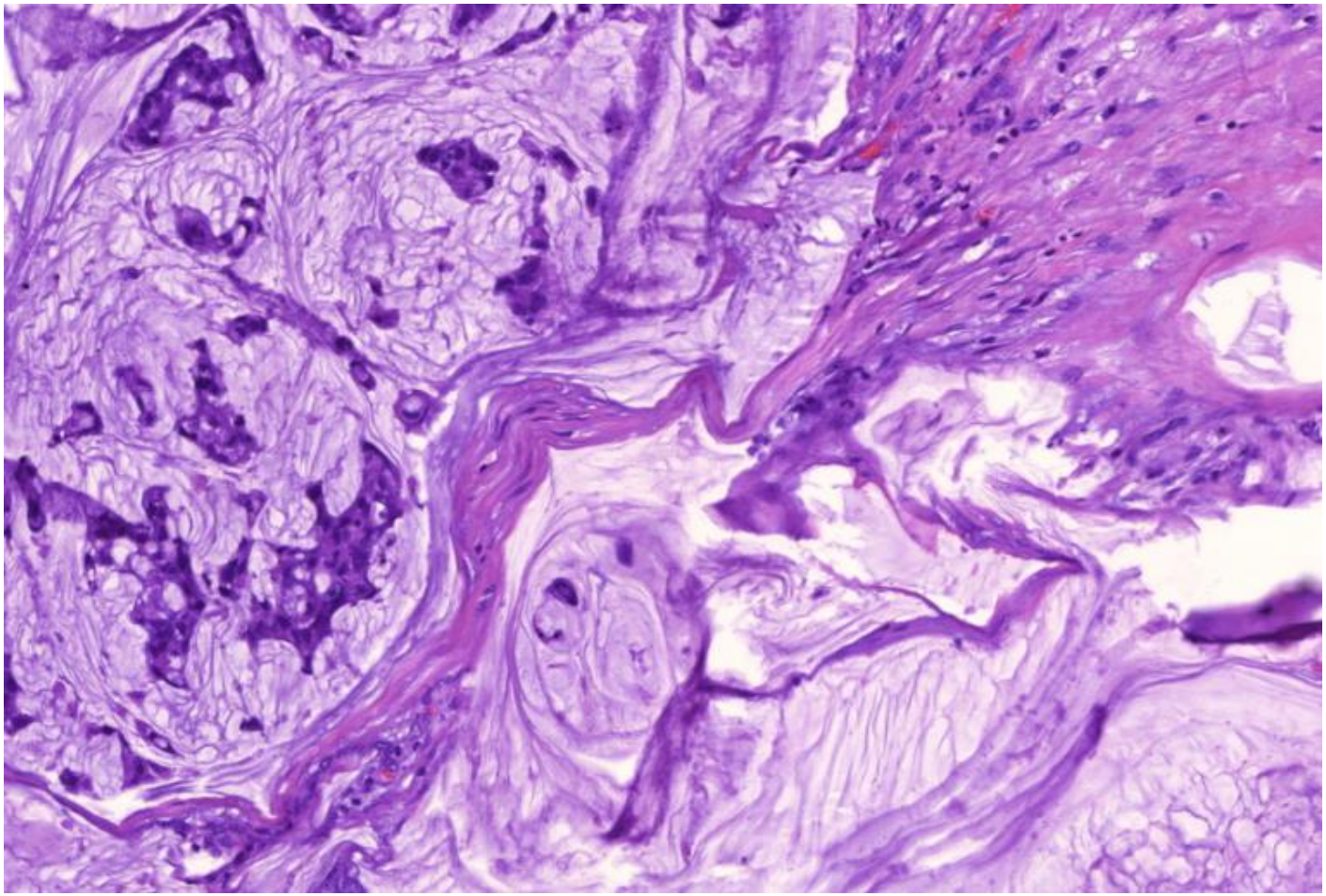

Case 1

- 55 årig mand indlægges med smerter under højre kurvatur i sidste uge - smerter aftog ved supp. diclodan, men pt. har i efterforløbet oplevet gule øjne og hud, samt universel hudkløe. Ingen feber. En enkelt opkastning i forløbet. Mørk urin. MRCP med mistanke om cholangiocarcinom med mulig indvækst i pancreas samt duodenum. Der laves Whipples operation.

- Snit fra resektatet

Case 1

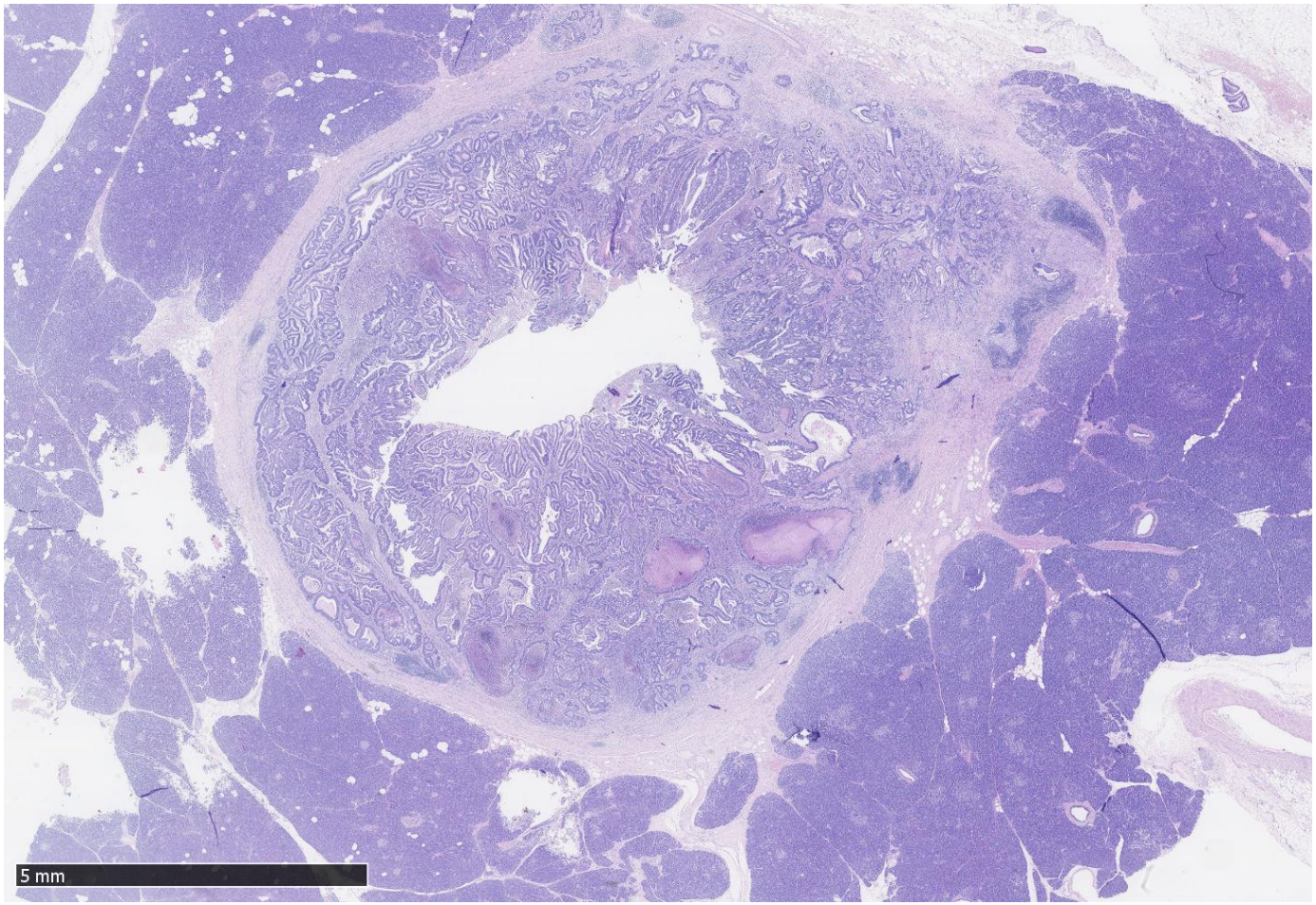

Case 1

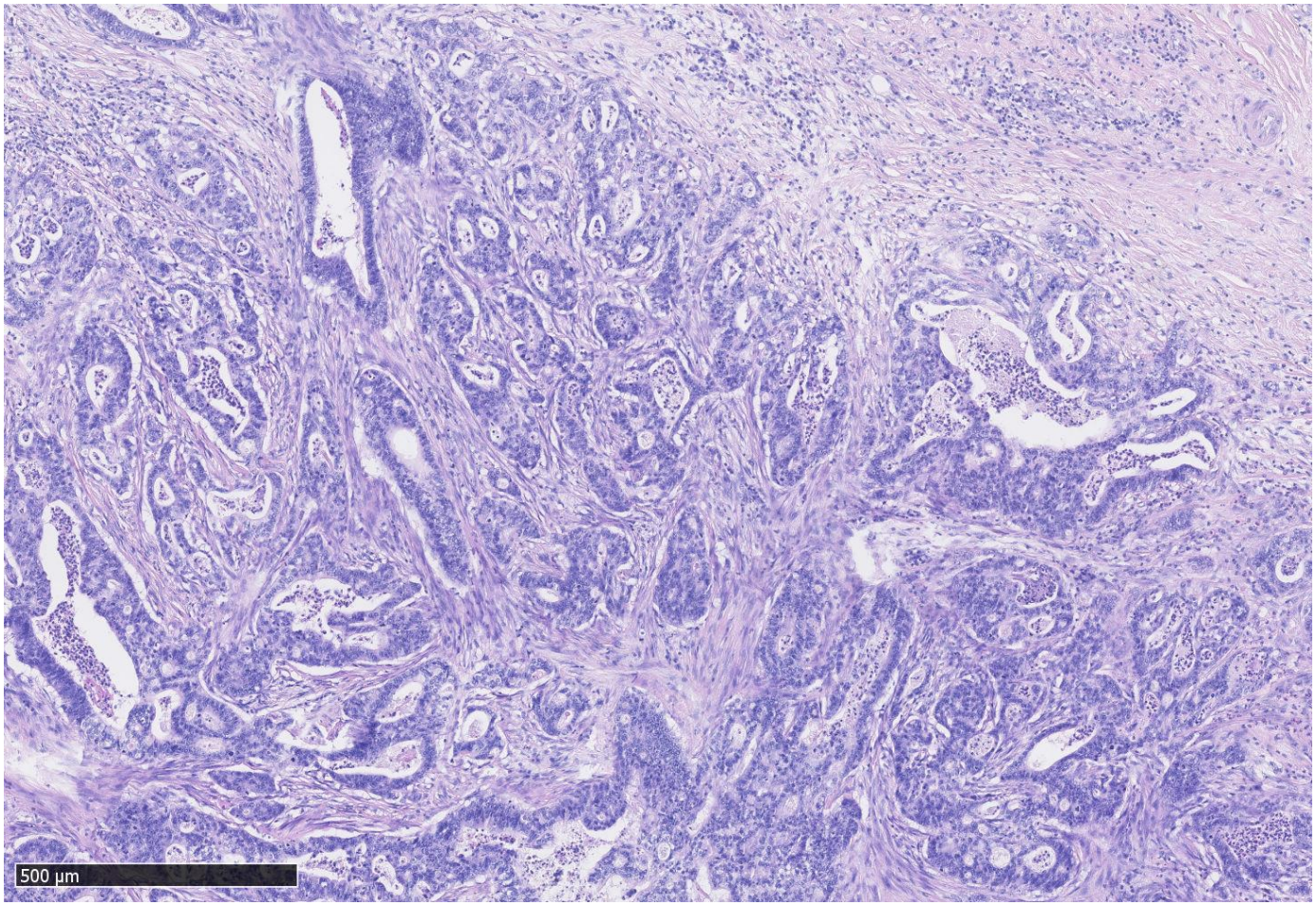

Diagnoseforslag

- Distalt cholangiokarcinom
- *IPN-B med invasion*
- PDAC
- PanIN3
- Tubulopapillær neoplasi

Case 10

- 39-årig kvinde henvist til vurdering på lever-pancreaskonference, hvor man beskriver MR-skanning og CT med en kombineret solid og cystisk proces i cauda pancreatis. Denne solide proces er på CT hypervaskulær. Det er lidt uvist hvad det drejer sig om, men det kunne repræsentere en NET eller pseudopapillær tumor. Patienten tilbydes en distal pancreas resektion med splenektomi, da hovedparten af forandringerne er beliggende i milthilius.

- Snit fra den beskrevne forandring

Case 10

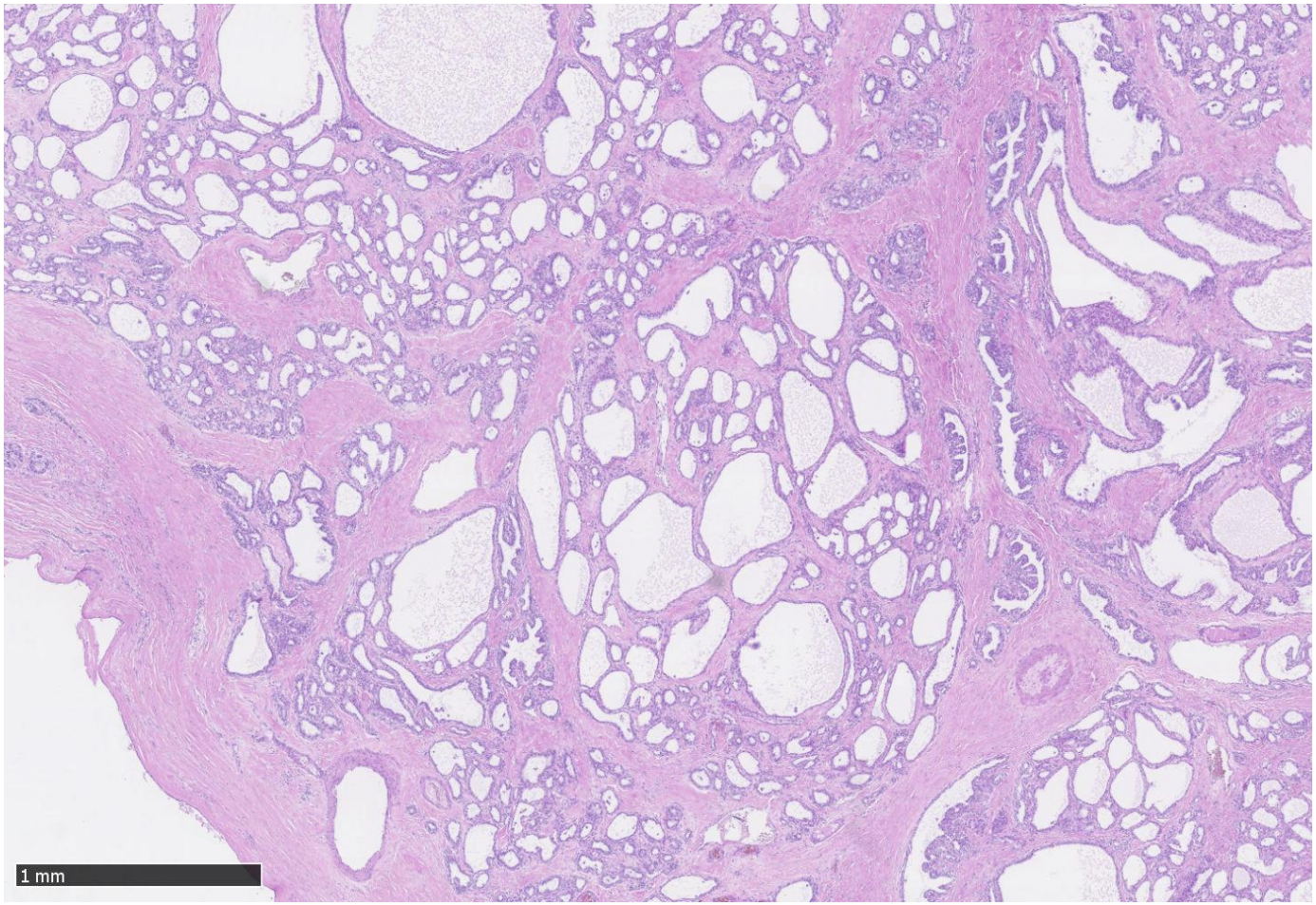

Case 10

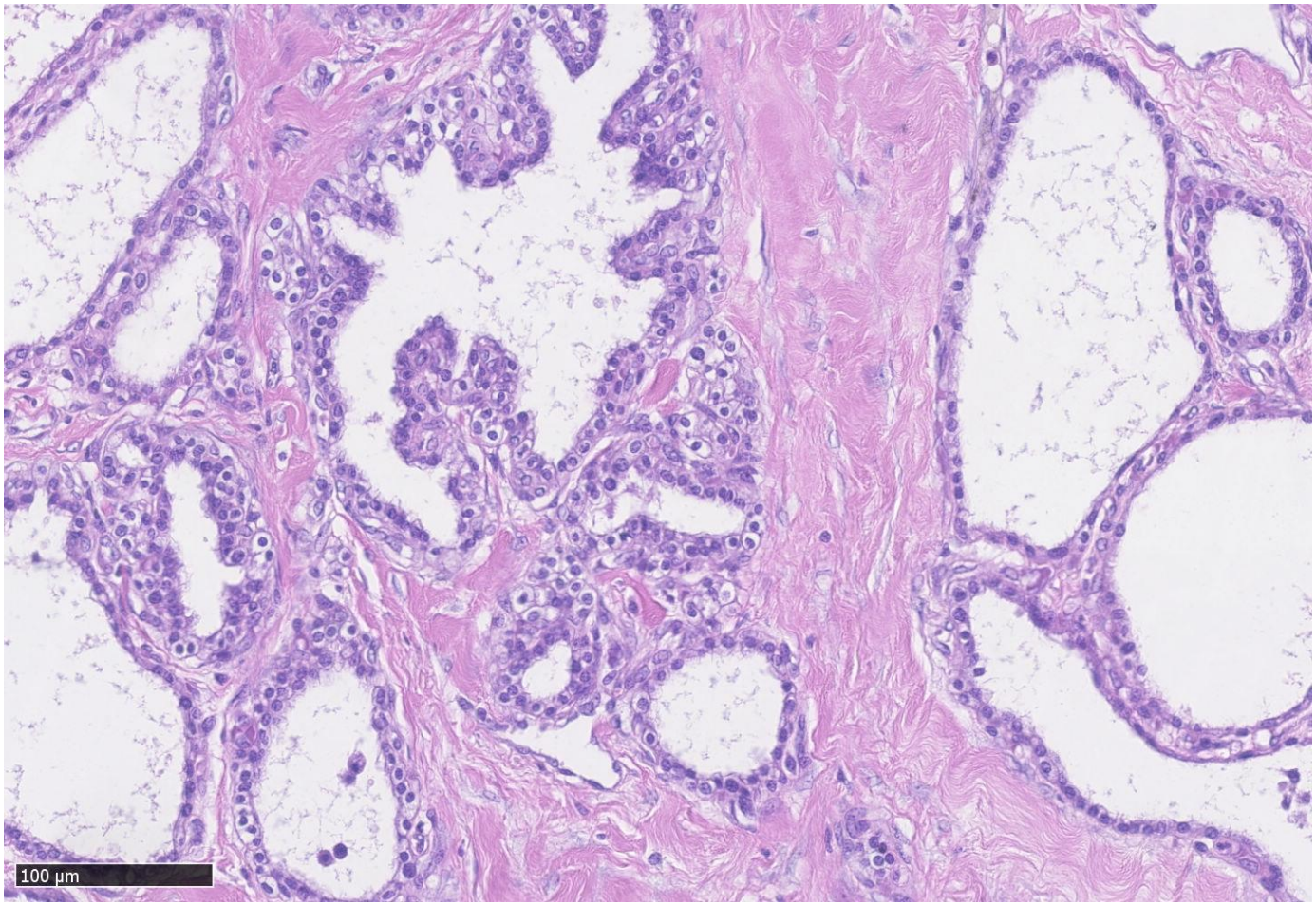

Diagnoseforslag

- Serøst cystadenom- *serøs cystisk neoplasi*
- Mucinøst cystadenom
- Blandet serøst cystadenom og neuroendokrin neoplasi
- Serøst karcinom
- Lymfangiom

Sekundære tumorer

- Opstår oftest ved direkte spredning
- Oftest metastaser fra GI-kanalen
- Andre
  - **Nyrer**
  - Prostata
  - Lunger
  - Leukæmi/lymfomer

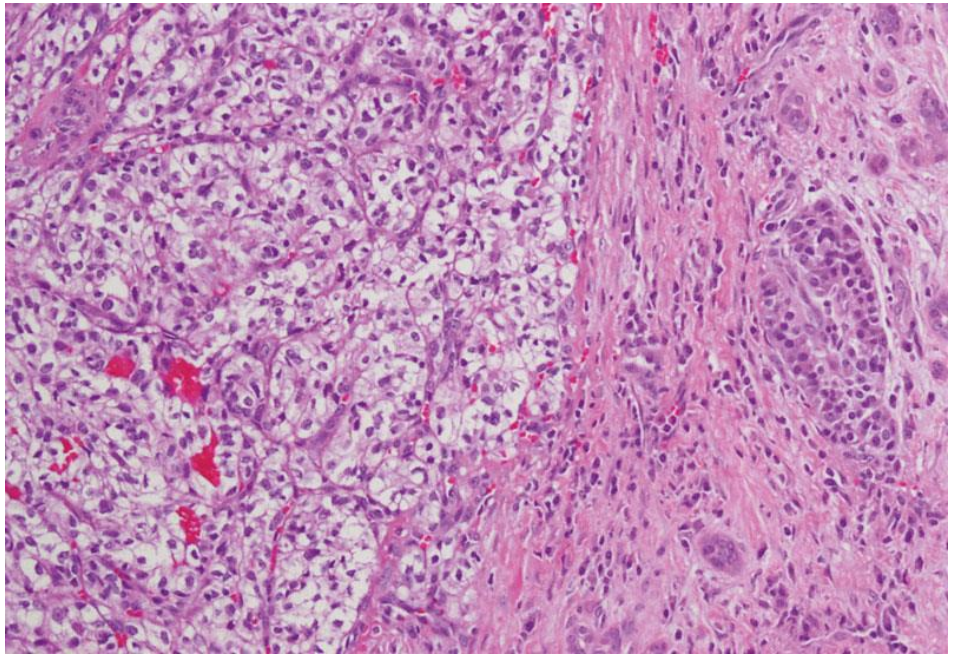

Mere info!

- www.DPCG.dk
  - Danske guidelines, database og årsmøde
- www.pathology.jhu.edu/pancreas
  - Gode billeder
- www.ESMO.org
  - Onkologiske guidelines
- www.EPC.org
  - Internationale møder
- Nordisk Pancreas Cancer Forum
  - Nyt forum, fokus på translationel forskning og samarbejde
- www.IHPBA.org
  - Nordisk underafdeling
  - Internationale møder